

Arteriovenous Uterine Malformation: A Complicated Case in Pregnancy

Cavaliere Anna Franca^{*}, Buongiorno Silvia, Vidiri Annalisa, Guariglia Lorenzo, Rosati Paolo and Scambia Giovanni

Department of Obstetrics and Gynaecology, Catholic University of the Sacred Heart-University Polyclinic, Gemini Rome, Italy

^{*}Corresponding author: Cavaliere Anna Franca, Department of Obstetrics and Gynaecology, Catholic University of the Sacred Heart-University Polyclinic, Gemini Rome, Italy, Tel: 390630154164; Fax: 390630157265; E-mail: afcavaliere@hotmail.com

Received date: June 12, 2017; Accepted date: June 26, 2017; Published date: June 30, 2017

Copyright: © 2017 Franca CA, et al. This is an open-access article distributed under the terms of the Creative Commons Attribution License, which permits unrestricted use, distribution and reproduction in any medium, provided the original author and source are credited.

Abstract

Arteriovenous uterine malformation (UAVM) is a rare congenital or acquired condition. This case report regards a pregnant patient of 37-year-old, gravida 2 para 0, suffering from AVM diagnosed 4 years before without any further embolization treatment; at 8 weeks of gestation, 2D-3D US examination confirmed severe AVM and detected a twin pregnancy: an embryo with normal cardiac activity in one sac and a blighted ovum. At 12 weeks of gestation, we also diagnosed additional fetal anomalies.

Keywords: 3D ultrasound; Arteriovenous uterine malformation; Doppler; Fetal malformation

Introduction

As neonatal intensive care has evolved, focus has shifted from improving mortality alone to an effort to improve both mortality and morbidity. Still in developing countries, the perinatal asphyxia continues being the third cause of the neonatal mortality, which is responsible for 23% with 4 million neonates suffering annually from birth asphyxia [1]. Hypoxic-ischemic encephalopathy (HIE) is the neurological manifestation of systemic hypoxia in new-born. The clinical criteria of Sarnat and Sarnat [2] measure the severity of HIE, classifying the patient in three stages according to level of consciousness, muscle tone, posture, tendinous reflexes, presence or absence of myoclonus and change of autonomic functions. Prevalence of perinatal asphyxia varies from 1 to 6 per 1000 live births while incidence of Hypoxic-ischemic injury is about 0.3 to 2 per 1000 full term infants [3]. According to some researchers, 20-25% of asphyxiated babies who exhibit severe HIE die during the new-born period. Babies who survived after severe HIE, upto 25% have permanent neuropsychological handicaps in the form of learning disabilities, epilepsy, cerebral palsy, with or without associated mental retardation. Systemic asphyxia that causes HIE may occur prior to delivery (placental abruption, toxemia), during delivery (prolonged labour, difficult delivery, abnormal presentation), or after delivery (sepsis, shock). In India between 250,000 to 350,000, infants die each year due to perinatal asphyxia mostly within the first three days of life. In addition, antepartum and intrapartum asphyxia contributes to as many as 300,000 to 400,000 stillbirths [4]. A clinician's ability to predict the outcome of neonates with HIE is not straightforward. For justifying the use of certain drugs for managing asphyxiated neonates, early recognition of HIE is important. Routinely APGAR score is used to evaluate asphyxia in neonates. But, APGAR score alone is not useful to ferret out neurological outcome, because it is influenced by various factors like immaturity, fetal malformations, maternal medications and infection [5].

A key step in the evolution of neonatal neuroprotection is the identification of biomarkers that enable the clinician-scientist to screen infants for brain injury, monitor progression of disease and assess

efficacy of neuroprotective clinical trials. Biomarkers are molecules released by or specific to a particular organ. These can be obtained from the blood, urine, cerebrospinal fluid or any other bodily fluid. In neonates with brain injury, biomarkers may be able to predict the degree and location of injury shortly after the injury occurs. Currently, clinicians do not routinely use biomarkers to care for neonates with brain injuries [6].

In new-born with perinatal asphyxia anaerobic glycolysis occurs as a result of hypoxic damage to cerebral oxidative metabolism, so only 2 molecules of Adenosine Triphosphate (ATP) are generated as compared to 32 molecules of ATP during aerobic conditions [7]. Further failure of oxidative phosphorylation and ATP production occurs as a consequence of prolonged hypoxia. Lack of ATP and increased cellular destruction will cause an accumulation of Adenosine Monophosphate (AMP) and Adenosine Diphosphate (ADP), which will then get catabolised to its constituents of adenosine, inosine and hypoxanthine [8,9]. Continuous tissue hypoxia and consequent reperfusion injury will result in hypoxanthine being oxidized to xanthine and uric acid in presence of xanthine oxidase. So uric acid production will be increased and cause it to enter blood from damaged tissues. This uric acid will then get excreted in urine where it can be easily detected [10,11].

This study will throw light on important role of urinary uric acid and creatinine ratio (UUA/Cr), that bedside clinician-scientist may use in resource poor setting in diagnosing perinatal asphyxia and stratify babies according to their severity so that neonates will be protected from exposure to unnecessary, ineffective therapies. We hope to contribute to the awareness, validation, and clinical use of these biomarkers.

Case Report

A 37 year old (gravida 2, para 0 with a previous twin spontaneous abortion), suffering from UAVM and with a history of metroplasty for a uterine septum, was admitted to our Department at 8 weeks of gestation. UAVM was diagnosed 4 years before with US, CT and MRI examination without any further preconceptional embolization treatment.

By conventional obstetrical US, we detected 2 separated gestational sacs at 8 weeks of gestation: the first one contained a fetus with regular fetal cardiac activity, the second one was a blighted ovum. At the same time, Doppler technology permitted us to define a mosaic pattern of flow inside the mass, showing apparently a prevalent arterial pattern demonstrated by an intralesional high peak systolic velocities (PVS: 81.2 cm/s); the lesion was located within the anterior myometrial wall.

Using 3D US rendering, specifically Glass Body and B-flow, we confirmed severe UAVM in pregnancy. In our case, these techniques were essential to better describe the relationship between the UAVM and the gestational sac, as well as the changing of the UAVM itself. In fact we found easily how the UAVM was lapping the uterine cavity, and the distance to the sac was as short as 3 mm. The only good finding was that placenta was mainly posterior, thus it was close to the malformation just on both edges. Moreover thanks to the 3D rendering we were able to detect an increase in the volume of the UAVM through the next weeks; this was seen both in the size of the whole malformation (side to side) and in the calibre of the major vessels within the malformation.

During the next scan at 12 weeks of gestation, severe fetal malformations were diagnosed: a posterior cystic formation (12 × 7 mm) probably caused by an incomplete closure of the bony cervical-thoracic elements of the spine, associated to a pathological abdominal herniation (18 × 16 mm) including bowel, liver and stomach covered by membrane.

We counseled the patient about the risks of maternal mortality and morbidity such as acute hemorrhage and hysterectomy, which were difficult to define exactly in percentage because of the rarity of the malformation, but reported as very high according to the published reports. Furthermore, we informed her about fetal congenital anomalies and related prognosis:

In the presence of onphalocele the incidence of chromosomal defects, mostly trisomy 18, is about 60% at 11-13+6 weeks of gestation and other spinal defects are associated with increased risk of aneuploidy [1].

The patient chose to perform a voluntary abortion (with previous radiological embolization) in a different hospital because not performed in our Catholic Institution.

Discussion

Uterine UAVMs are considered a rare condition, less than 100 cases are reported [2], but the real incidence is unknown. UAVMs may present with profuse hemorrhage, even during pregnancy and in the postpartum period. These lesions are classified as either congenital or acquired. Congenital UAVMs develop from failures in the embryological differentiation. The acquired ones, rare in nulliparous women, are thought to arise following uterine trauma such as dilation and curettage, cesarean section, cervical and endometrial carcinoma, trophoblastic disease, myomectomy, previous uterine ruptures, diethylstilbestrol exposure, inflammation, but it can be also idiopathic.

US is the most common method of initial investigation [3,4], and CT and MRI are being used with greater frequency [5]. Angiography should be reserved for planning any kind of surgical or embolizing intervention and embolization has become a more acceptable treatment, because it can reduce the indications for hysterectomy and preserve fertility. Low-level evidence supports the role of embolization,

including in the event of persistent bleeding following initial embolization, for the treatment of acquired UAVMs [6].

Several cases of pregnancy are reported after embolization [7]. In asymptomatic condition and without any reproductive planning, it may be not required any treatment. Few cases of spontaneous reduction of lesion and successful pregnancy after non-invasive management are described [8].

Because of the rarity of the disease, it is not possible to find guidelines or an “evidence based” management of these anomalies during pregnancy.

Scientific publications and reports are very poor about UAVM in pregnancy.

Geary et al. in 1996, underlined that during pregnancy the volume of the malformation could grow, especially for congenital UAVM [9], increasing the risk of rupture. An important variable could be the distance between placenta and UAVM itself [10].

The risk of haemorrhage is already well known during pregnancy and postpartum [11]. AVMs are so rare that they are only likely to contribute truly to less than 1% of PPH. Moreover, the diagnosis is usually only made in a hysterectomy or by interventional radiology [12].

However, some cases without severe complications were reported. In 2001, a woman with a small residual post-embolization UAVM delivered a 34 week old neonate [13]. In 2004 a patient with asymptomatic UAVM, diagnosed during pregnancy, was followed with monthly sonograms, and a caesarean delivery was performed without complications, avoiding the dilated vessels [10]. In 2004, Winsor et al. reported another case: the patient underwent to a caesarean section at 27 weeks of gestation and an immediately post-operative embolization was performed [14].

There is only one case of successful bilateral embolization during an on-going pregnancy at 20 weeks of gestational age, without complications neither during pregnancy nor at the caesarean section at 35 weeks [15].

Some cases reported normal evolution of pregnancy until delivery. In 2007 a 27-year-old woman, primigravida, with previous diagnosis of UAVM, delivered a healthy infant at 41 weeks spontaneously without any treatment but an excessive bleeding occurred for the eruption of the UAVM [16].

Other severe complications are reported. Kathiravan et al. in 2007 described a case with intraperitoneal UAVM rupture at 16 weeks of gestational age characterized by severe hemorrhage treated by isteroannessiectomy and intra-abdominal packs to achieve hemostasis. She suffered from further morbidities and complications that required intensive care [17]. Another case of a large UAVM was complicated by a rupture in early pregnancy was treated with radical surgery and the patient needed resuscitation [18].

These serious complications, particularly evident when the UAVM is increasing, should be considered in a correct counselling for pregnant women with UAVM.

Because of an increased risk of haemorrhage, another important variable is the distance and the relation between placenta and UAVM. In the study by Castro-Aragon et al. [10], because the AVM remained stable in size and only a small portion was adjacent to the placenta, it was thought that the time of delivery would be the largest risk. In our

case, we would like to underline the importance of the increase of the UAVM, which was behaving similarly to placental tissue in term of growing in size and amount of vascularization. Despite the positive finding that in our case placenta and UAVM were at the opposite side of the uterus, the observation of the changing in the volume of the malformation itself and the shortening of the distance between UAVM and gestational sac lead us to counsel the patient toward a poorer outcome rather than the case it had remained stable.

Our case is the first one in which UAVM is associated with early-diagnosed severe fetal malformations.

There are still no studies that associate UAVM with fetal malformations, and we cannot say whether they increase their risk, as they are not reported in the literature. Probably no genetic syndrome can be associated, but it cannot be excluded that altered vascularization can impact fetal development.

The patient, worried about possible complications for UAVM rupture, decided to interrupt pregnancy, considering the fetal anatomical alterations, which were all together life threatening and closely related to a poor outcome of pregnancy.

We are here also reporting the first published case which diagnosis was improved by using new ultrasound technique, such as 3D rendering combined with Doppler ultrasound. This way we could give an early diagnosis not only of the fetal malformation, but also to refine and better describe the UAVM and its changing during pregnancy, in order to counsel the patient (Figure 1).

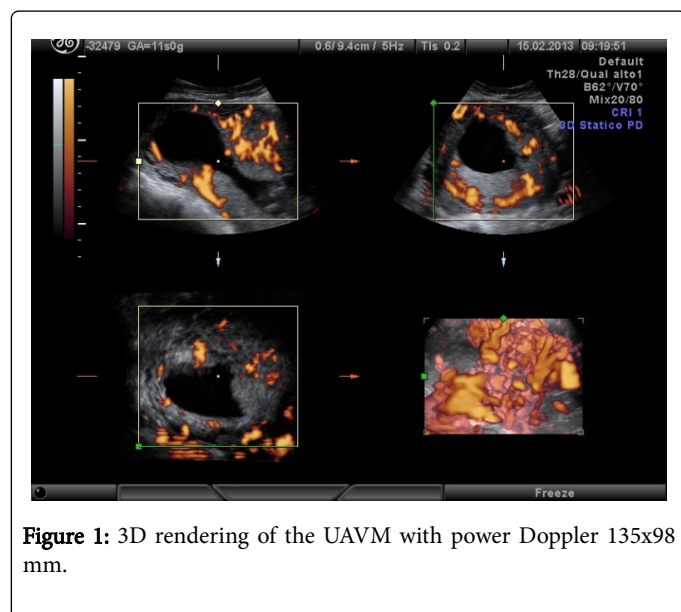


Figure 1: 3D rendering of the UAVM with power Doppler 135x98 mm.

To date the management of uterine UAVM should include preconceptional embolization. When an affected woman comes to the observation of the specialist already in pregnancy, as happened in our case, it should be mandatory to inform the patient about maternal risk in term of obstetric outcome and further fertility. However, it is necessary to include in the counselling the reported cases without a severe prognosis (Figure 2).

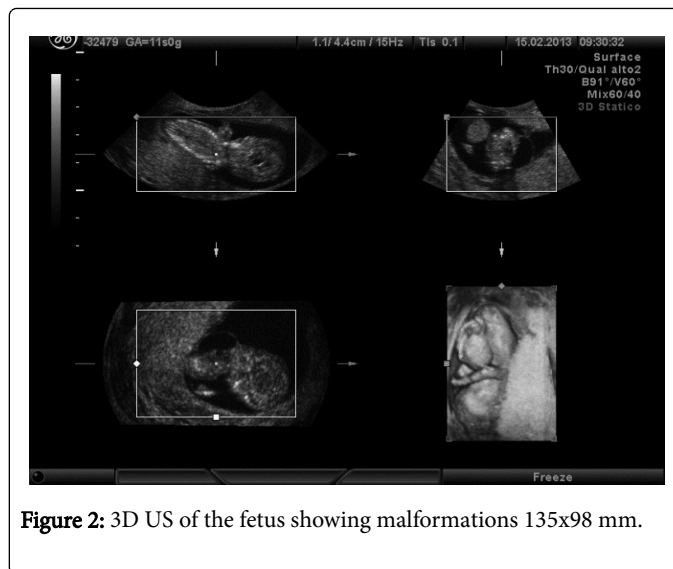


Figure 2: 3D US of the fetus showing malformations 135x98 mm.

In those cases the US management is mandatory, because it considers the dimensions of MAV, its variation during pregnancy, the relation between placenta or gestational sac and malformation, and the evaluation by 3D rendering combined with color-Doppleris is usfull to detect changing through the pregnancy and to suspect the presence of arterial flow (Figure 3).

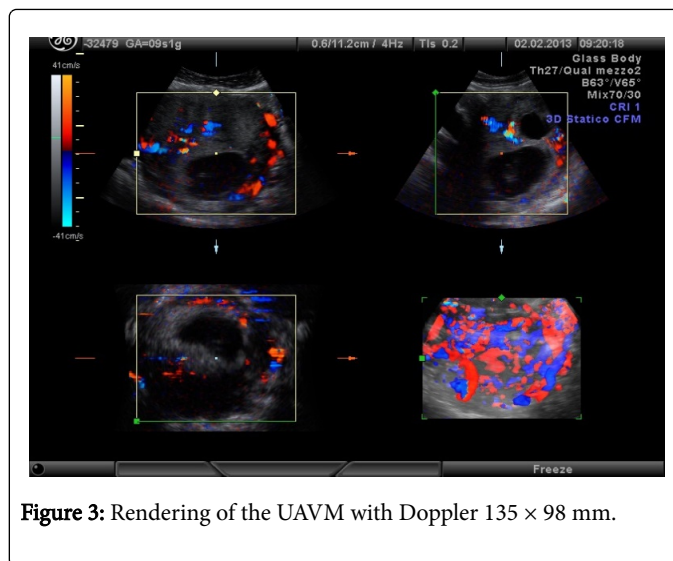


Figure 3: Rendering of the UAVM with Doppler 135 x 98 mm.

References

1. Snijders RJ, Sebire NJ, Souka A, Santiago C, Nicolaides KH (1995) Fetal exomphalos and chromosomal defects: Relationship to maternal age and gestation. *Ultrasound Obstet Gynecol* 6: 250-255.
2. Peitsidis P, Manolagos E, Tsekoura V, Kreienberg R, Schwentner L (2011) Uterine arteriovenous malformations induced after diagnostic curettage: A systematic review. *Arch Gynecol Obstet* 284: 1137-1151.
3. Timmerman D, Wauters J, Van Calenberg S, Van Schoubroeck D, Maleux G, et al. (2003) Color doppler imaging is a valuable tool for the diagnosis and management of uterine vascular malformations. *Ultrasound Obstet Gynecol* 21: 570-577.
4. Polat P, Suma S, Kantarcý M, Alper F, Levent A (2002) Color doppler US in the evaluation of uterine vascular abnormalities. *Radiographics* 22: 47-53.

5. Cura M, Martinez N, Cura A, Dalsaso TJ, Elmerhi F (2009) Arteriovenous malformations of the uterus. *Acta Radiol* 50: 823-829.
6. Yoon DJ, Jones M, Taani JA, Buhimschi C, Dowell AD (2016) A systematic review of acquired uterine arteriovenous malformations: Pathophysiology, diagnosis and transcatheter treatment. *AJP Rep* 6: e6-e14.
7. Delotte J, Chevallier P, Benoit B, Castillon JM, Bongain A (2006) Pregnancy after embolization therapy for uterine arteriovenous malformation. *Fertil Steril* 85: 228.
8. Onoyama I, Fukuhara M, Okuma A, Abbot J, levine D (2001) Successful pregnancy after the non-invasive management of uterine arteriovenous malformation. *Acta Obstet Gynecol Scand* 80: 1148-1149.
9. Geary M, McParland P (1996) Multiple and massive arteriovenous malformations in pregnancy. *Eur J Obstet Gynecol Reprod Biol* 64: 147-150.
10. Castro-Aragon I, Aragon I, Urcuyo R, Abbot J, levine D (2004) Conservative management of a uterine arteriovenous malformation diagnosed in pregnancy. *J Ultrasound Med* 1101-1104.
11. Kelly SM, Belli AM, Campbell S (2003) Arteriovenous malformation of the uterus associated with secondary postpartum hemorrhage. *Ultrasound Obstet Gynecol* 21: 602-605.
12. Hayes K (2002) Vascular malformations as a cause of postpartum haemorrhage. *Postpartum Haemorrhage* 2nd Edn.
13. Kelly FW (2001) Forceps delivery after molar malignancy in a woman with arteriovenous malformation, a case report. *J Reprod Med* 46: 1013-1016.
14. Winsor S, Francis JA, Tran C, Rawlinson J, Mohide PT (2004) Uterine arteriovenous malformation in pregnancy - A case series. *Ultrasound Obstet Gynecol* 24: 369.
15. Rebarber A, Fox NS, Eckstein DA, Saltzman DH (2009) Successful bilateral uterine artery embolization during an on-going pregnancy. *Obstet Gynecol* 113: 554-556.
16. Nasu K, Yamaguchi M, Yoshimatsu J, Miyakawa I (2007) Pregnancy complicated by asymptomatic uterine arteriovenous malformation: A case report. *J Reprod* 52: 335-337.
17. Kathiravan C, Emilia SH, Mutum SS (2007) Arteriovenous malformation of the pregnant uterus. *Med J Malaysia* 62: 179-180.
18. Majmudar B, Ghanee N, Horowitz IR, Horowitz IR, Graham D (1998) Uterine arteriovenous malformation necessitating hysterectomy with bilateral salpingo-oophorectomy in a young pregnant patient. *Arch Pathol Lab Med* 122: 842-845.