

Cystosarcoma Phyllodes, Rapidly Growing Tumours with Diagnostic Challenges

Zarafshan Zubair^{1*}, Noorulain Ali¹, Elya Tanweer¹, Ujala Zubair² and Baresham Batool¹

¹Dow University of Health Sciences Karachi, Pakistan

²Jinnah Sindh Medical University, Pakistan

Abstract

Phyllodes tumor (PT) also known as cystosarcoma phyllodes are rare fibro epithelial lesions characterized by bilayer epithelium and leafy fronds, accounting for less than 1% of breast neoplasms. The World Health Organization (WHO) has sub classified it into benign, borderline and malignant. These tumors need to be differentiated with fibro adenomas due to potential for metastasis and recurrence and similar clinical presentation. These tumors have been challenging for surgeons and pathologists because it is difficult to predict their behavior on core needle biopsies, while advances in immunohistochemical techniques may increase diagnostic accuracy in these lesions. Benign phyllodes do not metastasize but can reoccur locally and more aggressively. While the minority of patients with metastatic disease can develop symptoms within few months to years after initial treatment. Metastatic disease typically occurs in lung, mediastinum and bones. Most common treatment for these tumors is wide local excision, with mastectomy indicated for patients with larger lesions.

Keywords: Phyllodes tumor; Cystosarcoma; Immunohistochemical; Metastatic; Mastectomy

Introduction

Phyllodes tumors (PT) are uncommon fibro epithelial biphasic breast tumors which constitute less than 1% of all breast malignancies and are distinguished by varied extent of biologic behaviour [1]. Most of the tumor arises in women aged between 35 and 55 years [2]. Generally, phyllodes tumor presents as a relatively circumscribed painless mass. On an average, the size of the tumor measures 4 cm to 5 cm; however, large tumors >10 cm have been observed [3].

PT of the breast most often showed MED12 mutations, irrespective of the tumor grade. There is a slight similarity between PT and fibroadenomas as far as genetic influence is concerned [4]. The total rate of MED12 mutations was evidently identical in phyllodes tumors (62.5%) and fibroadenomas (59%) [5]. With the help of targeted next-generation sequencing, it was established that malignant phyllodes tumors cherished additional genetic aberrations in tumor suppressor genes which correlates with their aggressive biological behavior [6]. EZH2 and ALDH1 expression in the stroma of PT may signify malignant growth which in difficult circumstances aid in telling apart the benign from borderline and malignant tumors on histological grounds [7]. Phyllodes tumors are grouped into benign, borderline and malignant each having specific histological criteria i.e. the degree of stromal cellularity and atypia, mitotic count, stromal overgrowth, and the nature of their tumor borders [8]. Correct preoperative radiological and pathological diagnosis helps in improved surgical planning and refraining from unwanted reoperation. Imaging plays a vital part in diagnosis and management of phyllodes tumor [9]. Studies looking into the positive predictive value (PPV) of mammographic features, mentioned in the mammography BI-RADS lexicon, have noticed that PPV is helpful in discriminating between benign and malignant breast lesions [10]. ACR developed a BI-RADS lexicon for breast sonography in order to systemize the characterization of sonographic breast lesions. This lexicon includes captions of traits such as mass, shape, orientation, margin and posterior acoustic transmission. The patients' data, medical history, breast ultrasound findings and histological diagnosis were kept in an electronic database for each case and contrasted with the allotted ultrasound BI-RADS category [11].

Lesions originally diagnosed by core needle biopsy as atypia, malignant or having disagreeable imaging and histology underwent

surgical excision. The main treatment of phyllodes tumors remains surgical excision. Wide local excision, with a margin of at least 1 cm is the most effective surgery for both benign and malignant lesion. Radiotherapy (RT) is not needed for benign phyllodes tumors that are extensively excised. However, adjuvant RT appears to be effective in decreasing recurrences after breast conserving resection for borderline or malignant phyllodes tumors and especially when it is not feasible to achieve a wide margin of ≥ 1 cm of resection [12]. The majority of patients with benign and borderline phyllodes tumors are restored to health surgically. The 5-year survival rate for malignant phyllodes tumors is estimated to be 60% to 80% [13]. Metastases very often involve the lungs and liver. After the tumor has metastasized, average net survival is 30 months [14].

Case Report

A 40-year-old female reported to our hospital's outpatient department for evaluation of right breast lump which has been palpable for last two years. The female is premenopausal gravida 4 para 4 with a negative family history for breast cancer. The mass had been following a slowly enlarging course however, since last 8 months the mass has acquired a rapid course of enlargement and the patient has been reporting of intermittent pain which led the patient to consultation. The breast mass was significantly large, it did not erode the overlying skin and no discoloration. Patient also reported of menorrhagia since last three years and the menstrual cycle was irregular. On physical examination, the mass was 10 cm \times 7 cm palpable in the retro areolar area covering right upper and lower quadrants along with the nipple area. It was firm, mobile, non-tender mass with well demarcated borders, no skin thickening or nipple retraction. Blood report revealed

*Corresponding author: Zarafshan Zubair, Dow University of Health Sciences Karachi, Pakistan, Tel: +922199215754; E-mail: zarafshan96@hotmail.com

Received November 25, 2016; Accepted December 21, 2016; Published December 26, 2016

Citation: Zubair Z, Ali N, Tanweer E, Zubair U, Batool B (2016) Cystosarcoma Phyllodes, Rapidly Growing Tumours with Diagnostic Challenges. J Clin Case Rep 6: 908. doi: 10.4172/2165-7920.1000908

Copyright: © 2016 Zubair Z, et al. This is an open-access article distributed under the terms of the Creative Commons Attribution License, which permits unrestricted use, distribution, and reproduction in any medium, provided the original author and source are credited.

microcytic hypochromic anaemia (Hb=9.4 gm/dl, HCT=30.7, MCH=20.0, MCHC=30.6). Other labs like UCE's PT, INR, LFT's were normal. X-rays revealed no radiopaque lesion in the chest.

The mammogram of right breast showed a large soft tissue density mass with lobulated outlines in retro areolar region extending into all quadrants with multiple foci of dystrophic calcification. No skin thickening or nipple retraction reported. Mammogram revealed BIRADS-V cystosarcoma phyllodes tumor (highly suggestive of malignancy). Benign looking axillary lymph nodes were present. On complementary ultrasound, a complex hyperechoic mass with heterogeneous architecture, multiple intralesional cystic spaces and lobulated outline measuring 10.9 cm × 7.2 cm. Figures 1 and 2 shows the mammogram mediolateral and craniocaudal views respectively). Color Doppler showed intralesional vascularity with low resistance waveform in mass and RI of 0.5. Biopsy of the lesion showed multiple cores predominantly showing hyalinized stroma, spindle shaped cells with bland nuclei and pale cytoplasm. Foci of calcification noted. Occasional ducts are seen lined by epithelial and myoepithelial cells. No evidence of granuloma or malignancy. Investigations of the left breast did not show any such lesion. The patient subsequently underwent a simple mastectomy, wide resection with clear margins of >1 cm. No complications reported

Background

Phyllodes tumor (PT) also known as cystosarcoma phyllodes are rare fibro epithelial lesions characterized by bilayer epithelium and leafy fronds, accounting for less than 1% of breast neoplasms. The World Health Organization (WHO) has sub classified it into benign, borderline and malignant. These tumors need to be differentiated with fibro adenomas due to potential for metastasis and recurrence and similar clinical presentation. These tumors have been challenging for surgeons and pathologists because it is difficult to predict their behavior on core needle biopsies, while advances in immunohistochemical

techniques may increase diagnostic accuracy in these lesions. Benign phyllodes do not metastasize but can reoccur locally and more aggressively. While the minority of patients with metastatic disease can develop symptoms within few months to years after initial treatment. Metastatic disease typically occurs in lung, mediastinum and bones. Most common treatment for these tumors is wide local excision, with mastectomy indicated for patients with larger lesions.

Discussion

Phyllodes, a rare tumor of breast is said to be responsible for less than 1% of all female breast tumors. Even in a country like Pakistan where breast cancer incidence is rising, there are few case series reported suggesting the infrequent occurrence of these tumors. The principal diagnostic modalities for breast pathologies are through clinical examination, USG, mammography, FNAC and histopathology. The initial provisional diagnosis must always be confirmed by histopathology. Breast imaging studies may fail to distinguish the phyllodes tumor from a fibroadenoma. Phyllodes tumors are usually differentiated histologically by core needle biopsy from fibroadenoma by its increased stromal cellularity and mitotic activity.

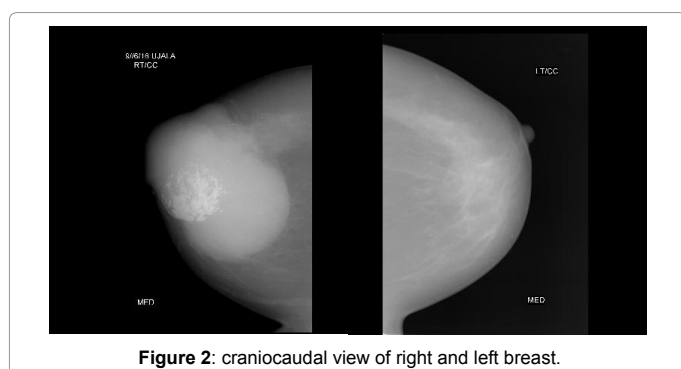
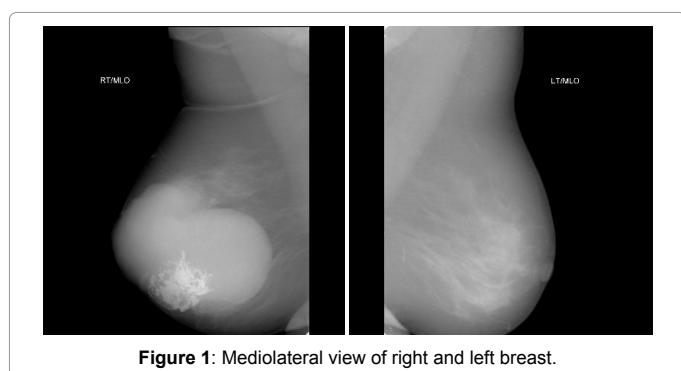
The World Health Organization have categorized these tumors on histological basis as low, intermediate and high grade. The prognostic factors of significance are several histopathologic parameters e.g., stromal cellularity, stromal cellular atypia, mitotic activity, atypical mitoses, stromal overgrowth, tumor contour, tumor necrosis, and heterologous stromal elements [15,16]. The mainstay of PT management is conservative surgical resection with safe margin 1 cm to 2 cm recommended for benign, border line and malignant phyllodes [17]. Previous studies point out that axillary dissection is not advised because it hardly metastasize and account for 10% of cases [18]. Studies suggest that adjuvant radiotherapy proves to be beneficial in patients with adverse features (e.g., bulky tumors, close or positive surgical margins, hyper cellular stroma, high nuclear pleomorphism, high mitotic rate, presence of necrosis, and increased vascularity within the tumor and tumor recurrence) but their use is controversial [2]. The presence of tumor cells on the resection margin was a strong prognostic factor for local recurrence of PTs [19]. The time-period between treatment of the primary tumor and likely presentation of distant metastases changes considerably and spans from 1 month to over 10 years; however, most of the cases of DM of PT are noted within the first 3 years [20]. In the patients with DM from a PT, chemotherapy has been considered the first-line treatment for many years [21]. Neoplastic cells disposed to local recurrence because of their presence in the perivascular tissue [22]. Prevention of local recurrence is very important in the management course, and radiotherapy should be considered in averting the recurrence [23].

Conclusion

We presented a case of PT, highlighting an approach to distinguish between phyllodes and other common benign conditions. Clinical features along with imaging and histological investigations confirm the diagnosis, which will lead to pre-planned surgical and medical options and a better prognosis.

References

1. Demian GA, Fayaz S, Eissa HE-S, Nazmy N, Samir S, et al. (2009) Phyllodes tumors of the breast: Analysis of 35 cases from a single institution. *Journal of the Egyptian National Cancer Institute* 28: 243-248.
2. Mishra SP, Tiwary SK, Mishra M, Khanna AK (2013) Phyllodes tumor of breast: A review article. *ISRN surgery*.



3. Murthy SS, Raju K, Nair HG (2016) Phyllodes tumor in a lactating breast. Clin med insights Pathol 9: 13-17
4. Yoshida M, Sekine S, Ogawa R, Yoshida H, Maeshima A, et al. (2015) Frequent MED12 mutations in phyllodes tumours of the breast. Br J cancer 112: 1703-1708.
5. Lim WK, Ong CK, Tan J, Thike AA, Ng CCY, et al. (2014) Exome sequencing identifies highly recurrent MED12 somatic mutations in breast fibroadenoma. Nature Genetics 46: 877-880.
6. Cani AK, Hovelson DH, McDaniel AS, Sadis S, Haller MJ, et al. (2015) Next-Gen sequencing exposes frequent MED12 mutations and actionable therapeutic targets in phyllodes tumors. Mol Cancer Res 13: 613-619.
7. Zhang Y, Liss AL, Chung E, Pierce LJ, Kleer CG (2008) Stromal cells in phyllodes tumors of the breast are enriched for EZH2 and stem cell marker expression. Breast Cancer Res Treat 158: 21-28.
8. Tan BY, Acs G, Apple SK, Badve S, Bleiweiss IJ, et al. (2016) Phyllodes tumours of the breast: A consensus review. Histopathology 68: 5-21.
9. Haider S, Tasleem M (2015) Borderline Phyllodes Tumour. J Cancer Allied Spec 1(2).
10. Liberman L, Abramson AF, Squires FB, Glassman J, Morris E, et al. (1998) The breast imaging reporting and data system: Positive predictive value of mammographic features and final assessment categories. Am J roentgenol 171: 35-40.
11. Balleyguier C, Ayadi S, van Nguyen K, Vanel D, Dromain C, et al. (2007) BIRADS™ classification in mammography. Eur J radiol 61: 192-194.
12. Pezner RD, Schultheiss TE, Paz IB (2008) Malignant phyllodes tumor of the breast: Local control rates with surgery alone. Int J Radiat Oncol Biol Phys 71: 710-713.
13. Confavreux C, Lurkin A, Mitton N, Blondet R, Saba C, et al. (2006) Sarcomas and malignant phyllodes tumours of the breast—a retrospective study. Eur J cancer 42: 2715-2721.
14. Kessinger A, Foley JF, Lemon HM, Miller DM (1972) Metastatic cystosarcoma phyllodes: A case report and review of the literature. Journal of surgical oncology 4: 131-147.
15. Cohn-Cedermark G, Rutqvist LE, Rosendahl I, Silfverswärd C (1991) Prognostic factors in cystosarcoma phyllodes. A clinicopathologic study of 77 patients. Cancer 68 : 2017-2022.
16. Noora Almoosa M, Board S (2015) Phyllodes Tumor: One Experience Institute. BMB 37(1).
17. Chaney AW, Pollack A, Mcneese MD, Zagars GK, Pisters PW, et al. (2000) Primary treatment of cystosarcoma phyllodes of the breast. Cancer 89: 1502-1511.
18. McGregor GI, Knowling MA, Este FA (1994) Sarcoma and cystosarcoma phyllodes tumors of the breast: A retrospective review of 58 cases. Am J surg 167: 477-480.
19. Jang JH, Choi MY, Lee SK, Kim S, Kim J, et al. (2012) Clinicopathologic risk factors for the local recurrence of phyllodes tumors of the breast. Ann surg oncol 19: 2612-2617.
20. Barrio AV, Clark BD, Goldberg JI, Hoque LW, Bernik SF, et al. (2007) Clinicopathologic features and long-term outcomes of 293 phyllodes tumors of the breast. Ann surg oncol 14: 2961-2970.
21. Reinfuss M, Mitus J, Stelmach A (1995) Phyllodes tumor of the breast. Radiat Ther Oncol 171: 5-11.
22. Bolton B, Sieunarine K (1990) Carcinosarcoma: A rare tumour of the breast. Aust N Z J Surg 60: 917-919.
23. Buzdar A, Valero V, Theriault R, Frye D, Green M, et al. (2003) Pathological complete response to chemotherapy is related to hormone receptor status. Breast Cancer Res Treat 82: S69.

Citation: Zubair Z, Ali N, Tanweer E, Zubair U, Batool B (2016) Cystosarcoma Phyllodes, Rapidly Growing Tumours with Diagnostic Challenges. J Clin Case Rep 6: 908. doi: [10.4172/2165-7920.1000908](https://doi.org/10.4172/2165-7920.1000908)

OMICS International: Open Access Publication Benefits & Features

Unique features:

- Increased global visibility of articles through worldwide distribution and indexing
- Showcasing recent research output in a timely and updated manner
- Special issues on the current trends of scientific research

Special features:

- 700+ Open Access Journals
- 50,000+ editorial team
- Indexing at major indexing services
- Rapid review process
- Quality and quick editorial, review and publication processing
- Indexing at major indexing services
- Sharing Option: Social Networking Enabled
- Authors, Reviewers and Editors rewarded with online Scientific Credits
- Better discount for your subsequent articles

Submit your manuscript at: <http://www.omicsonline.org/submit/>