

## Laparoscopic Colectomy for Colon Cancer with Retroperitoneal Abscess Treated with Initial Conservative Therapy: A Report of Three Cases with a Literature Review

Genta Sawada<sup>1\*</sup>, Ken Nakata<sup>1\*</sup>, Masaki Tsujie<sup>1</sup>, Koji Amano<sup>2</sup>, Jota Mikami<sup>1</sup>, Tomoya Kishimoto<sup>1</sup>, Shin Nakahira<sup>1</sup>, Yoichi Makari<sup>1</sup>, Junya Fujita<sup>1</sup> and Hiroki Ozato<sup>1</sup>

<sup>1</sup>Department of Surgery, Sakai City Medical Center, Japan

<sup>2</sup>Department of Trauma and Acute Care Surgery, Sakai City Medical Center, Japan

### Abstract

**Background:** Colon cancer rarely invades the retroperitoneum and surrounding organs, such as the iliopsoas muscle, resulting in retroperitoneal abscesses. We present three cases of colon cancer with retroperitoneal abscesses (CRA, treated using different initial conservative therapies (ICTs, followed by laparoscopic surgery. We also reviewed 18 cases of CRA reported in Japanese literature from 2000 to 2016.

**Case presentation:** In Case 1 and 2, patients underwent abscess drainage as ICT. In Case 3, the patient diagnosed with cecum cancer underwent initial treatment with separation surgery, which isolated the right side of the colon from the left side and created a mucus fistula of the right-side colon to prevent stool from running through the lesion. In all cases, ICT combined with antibiotic therapy improved the general condition of the patients and reduced the volume of the abscess cavity, enabling a laparoscopic surgery to be performed. All cases underwent en bloc resection of the main tumor and invaded organ with adequate lymph node dissection. Rather than attempting complete resection of the entire abscess cavity, the debridement of the abscess cavity was performed. Although one patient complained of mild neuropathic pain of the left thigh after surgery, the postoperative clinical courses of the three patients were almost uneventful. The follow-up periods of Case 1, 2, and 3 were 24, 6, and 2 months respectively, and they have shown no signs of recurrence after surgery.

**Conclusion:** Following a review of 18 CRA cases, ICT for CRA didn't make any significant differences in postoperative complication and length of hospital stay compared with surgery alone. However, based on our cases, ICT before surgery clearly provided benefit to the patients and made the use of laparoscopic surgery possible. ICT can be a useful strategy for the treatment of CRA.

**Keywords:** Colon cancer; Retroperitoneal abscess; Laparoscopic surgery; Conservative therapy

**Abbreviations:** CRA: Colon Cancer with Retroperitoneal Abscess, ICT: Initial Conservative Therapy, SA: Surgery Alone, CEA: Carcinoembryonic Antigen, CA19-9: Carbohydrate Antigen 19-9, WBC: White Blood Cell, CRP: C Reactive Protein

### Introduction

Colon cancer with retroperitoneal abscesses (CRA) is a rare condition where the retroperitoneum and surrounding organs are invaded by the colon cancer [1]. However, it sporadically appears in clinical practice, and it is difficult to treat because the standard therapeutic strategy is not established. Based on previous reports [2], therapeutic strategies for CRA are generally one of following two methods [3]: surgery alone, or initial conservative therapy (ICT followed by surgery. ICT such as drainage of abscesses is the therapy to resolve high grade inflammation due to abscess and improve patient's general condition before the radical resection. ICT seems to have benefits compared to surgery alone, but still requires careful consideration [4]. In addition, equally importantly, the type of surgical procedures that need to be performed is another point of interest. Since there is limited data regarding the presence of viable cancer cells in the abscess cavity [5], it remains to be elucidated whether a complete resection of the abscess cavity is required or debridement of the abscess cavity is sufficient. This may also be a key determinant of whether laparoscopic surgery is a feasible option for the procedure.

We present three cases of patients with CRA who underwent laparoscopic surgery following ICT in our institute. We also reviewed 18 previous cases of CRA, published from 2000 to 2016 in the Japanese literature, allowing for a comprehensive discussion of the management of CRA.

### Case Report

#### Two cases of CRA treated with drainage of abscesses as ICT Cases 1 and 2

Case 1 was 76-year-old male who came to our hospital with an uncomfortable feeling in his left inguinal region. A hard mass was palpable in his left lower abdomen; however, no rebound pain or voluntary guarding was observed. Laboratory examinations suggested high-grade inflammation (Table 1), but normal levels of carcinoembryonic antigen (CEA and carbohydrate antigen 19-9 (CA19-9, at 3.8 ng/ml and 7.0 U/ml, respectively. Computer tomography (CT revealed an abscess in the left iliacus muscle accompanied with a thickened sigmoid colon wall, which made us suspect sigmoid colon cancer with a retroperitoneal abscess (Figure 1a). Following antibiotic therapy and drainage of the abscess as ICT, his physical symptoms resolved and his white blood cell (WBC counts and serum levels of C-reactive protein (CRP improved, as shown in Table 1. Subsequent endoscopic survey confirmed type 2

\*Corresponding author: Genta Sawada, Ken Nakata, Department of Surgery, Sakai City Medical Center, Japan, Tel: +81-72-272-1199; Fax: +81-72-272-9911; E-mail: [gsawada@gesurg.med.osaka-u.ac.jp](mailto:gsawada@gesurg.med.osaka-u.ac.jp)

Received May 06, 2017; Accepted June 12, 2017; Published June 16, 2017

**Citation:** Sawada G, Nakata K, Tsujie M, Amano K, Mikami J, et al. (2017) Laparoscopic Colectomy for Colon Cancer with Retroperitoneal Abscess Treated with Initial Conservative Therapy: A Report of Three Cases with a Literature Review. J Clin Case Rep 7: 975. doi: [10.4172/2165-7920.1000975](https://doi.org/10.4172/2165-7920.1000975)

**Copyright:** © 2017 Sawada G, et al. This is an open-access article distributed under the terms of the Creative Commons Attribution License, which permits unrestricted use, distribution, and reproduction in any medium, provided the original author and source are credited.

Cases	Age	Sex	Tumor Location	Initial Therapy	Laboratory Examination	After Initial Therapy	Operation Procedure	Culture Study Of Abscess	Operation Time And Blood Loss	Hospital Stay (Day)	Complication	Chemotherapy	Observation Period (Month)	outcome
<b>Before initial therapy</b>														
Case 1	73	M	Sigmoid	Drainage	WBC:23200	WBC:7010	Laparoscopic Sigmoidectomy	<i>Gemella</i>	3h 48m	13	mild	mFOLFOX6 *	24	alive
					CRP: 26.6	CRP: 0.10		<i>Mobilorum Streptococcus</i>	130 ml					
								<i>sp</i>						
								<i>Bacteriodes spp</i>						
<i>Prevotella spp</i>														
Case 2	61	M	Cucem	Drainage	WBC: 16740	WBC: 8680	Laparoscopic Sigmoidectomy	<i>Gemella</i>	3h 46m 100 ml	7	-	mFOLFOX6 *	6	alive
					CRP: 27.04	CRP: 0.52		<i>Mobilorum</i>						
								<i>Candida sp</i>						
								<i>Bacteriodes spp</i>						
<i>sp</i>														
Case 3	69	F	Cucem	Separation Surgery	WBC: 9480	WBC: 6070	Laparoscopic Sigmoidectomy	Not exam	4h 33m 150 ml	13	-	XELOX **	2	alive
					CRP: 3.71	CRP: 0.52								

Table 1: Clinical features of three cases with CRA.

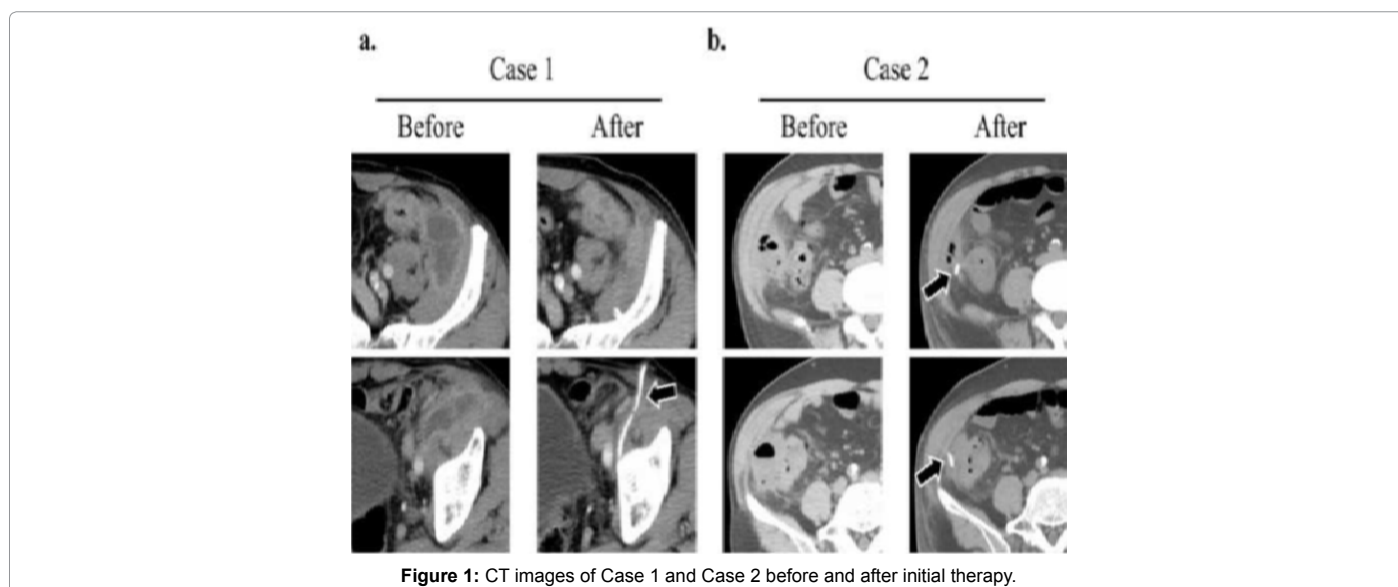


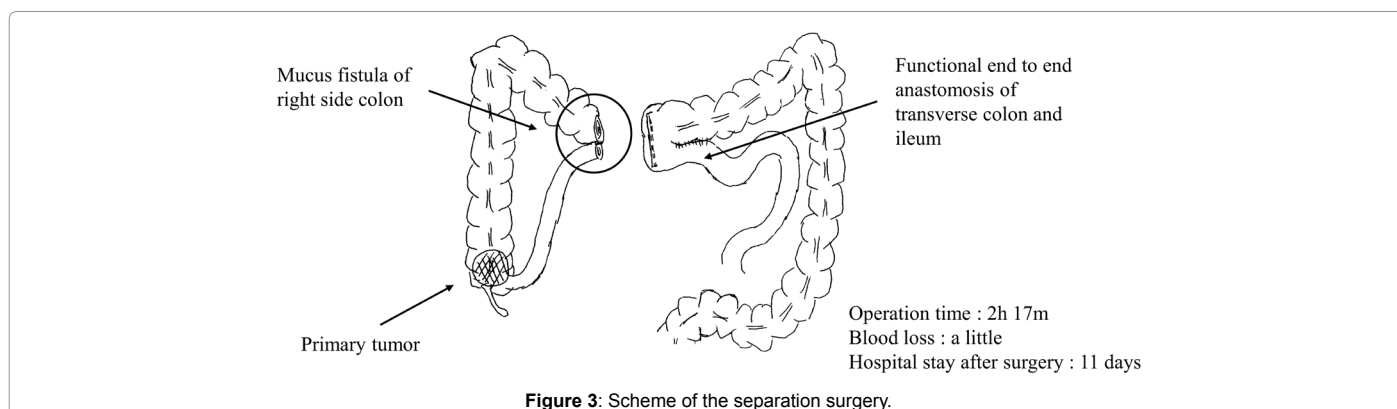
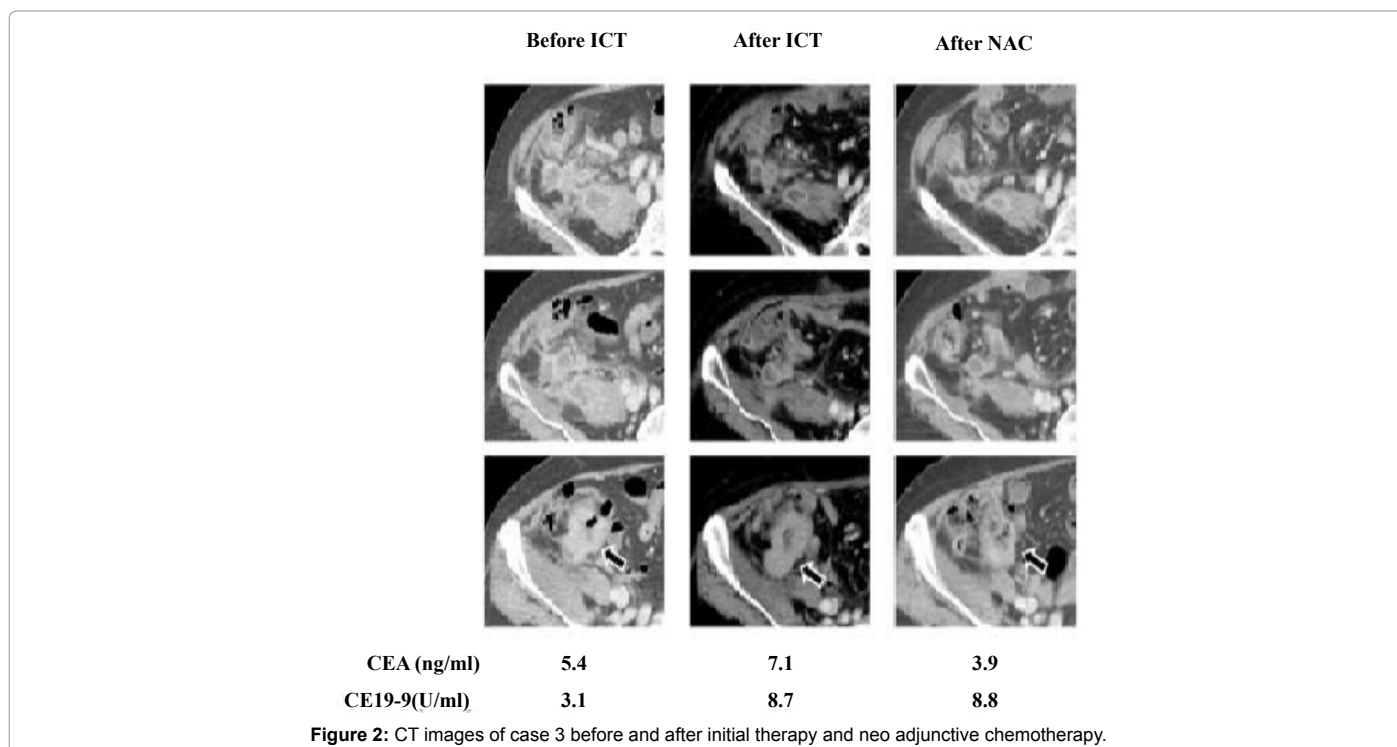
Figure 1: CT images of Case 1 and Case 2 before and after initial therapy.

adenocarcinoma located at sigmoid colon and follow-up CT identified shrinkage of the abscess (Figure 1a). Laparoscopic sigmoidectomy with lymph node dissection was performed 10 days after the drainage of the abscess. Operative findings suggested that sigmoid colon was firmly attached to the lateral abdominal wall and the retroperitoneum. The sigmoid colon was removed by performing resection of the lateral wall and iliocostus muscle. The debridement of the abscess cavity was also performed, however, no purulent discharge was found during the operation. Postoperatively, the patient complained of a mild neuropathic pain in his left thigh, but it gradually improved without treatment. The patient was discharged 11 days after surgery. Microscopic examination of the resected specimen found serosal invasion of the tumor with lymph node metastasis (pT4a pN2 cM0 pStage IIIb, according to Japanese Classification of Colorectal Cancer 8th edition. Adjuvant chemotherapy of oxaliplatin, 5-fluorouracil and folinic acid (modified FOLFOX-6 was

administered for six months. There have been no signs of recurrence in the 24 months that this patient has been followed up for, postoperatively.

### Case 2

Case 2 was 61-year-old male suffering from right abdominal pain upon admission to our hospital. As in Case 1; laboratory examination demonstrated high-grade inflammation (Table 1). CT scans revealed collection of fluid within the right lateral abdominal wall with a few diverticula at the cecum and ascending colon (Figure 1b). The patient was diagnosed with diverticulitis penetrating the retroperitoneum based on these findings. The combination of abscess drainage and antibiotic treatment reduced the volume of the abscess cavity, and reduced symptoms (Table 1 and Figure 1b). However, radiography with the abscess drainage tube revealed that a fistula across the ascending colon to extra luminal space had remained. The patient underwent laparoscopic



surgery for resection of his ascending colon 15 days following the initiation of therapy. Intraoperative findings showed that the ascending colon was firmly adhered to retroperitoneum and lateral abdominal wall, requiring partial resection of the lateral wall and iliacus muscle as well as debridement of abscess cavity. As the resected specimen indicated a high possibility of cecum cancer during operation, lymph node dissection was also performed. No complications were observed in his postoperative course, and the patient was discharged 7 days after surgery. Modified FOLFOX-6 was administered as adjuvant therapy, as the pathological findings suggested serosal invasion of the tumor with notable lymph nodes metastasis (pT4a pN3 cM0 pStage IIIb, according to Japanese Classification of Colorectal Cancer 8th edition. This patient has been followed-up for six months and no signs of recurrence after surgery have been observed.

### Cecum cancer, penetrating the retroperitoneum, treated with right-colon separation surgery as ICT (Case 3)

A 69-year-old female patient was admitted to our hospital because of cecum colon cancer, which had been diagnosed previously by

colonoscopy. Laboratory examinations indicated relatively mild inflammation compared to the other two cases (Table 1). CT scan revealed wall thickening of cecum; multiple, separate abscesses; and swelling lymph nodes, indicative of lymph node metastasis (Figure 2). Because of separate abscess cavities, drainage was not expected to be successful. Separation surgery with mucus fistulotomy was performed, in which, as shown in (Figure 3), the right side of the colon is separated from left side, and a mucus fistula of right side of the colon is created to prevent stool from running through the lesion. This surgery combined with antibiotics therapy reduced abscess cavity volumes and improved laboratory findings. The patient was permitted oral intake and discharged 11 days after surgery. These initial therapies enabled the patient to receive neo-adjuvant therapy, initially started as capecitabine plus oxaliplatin (CapeOX with the addition of bevacizumab in the second cycle. However, bevacizumab treatment had to be discontinued after cycle 2 owing to the identification of a pulmonary embolism on CT scan. In total, four courses of CapeOX therapy were administered, with confirmed shrinkage of the primary tumor and decreased serum levels of CEA and CA19-9 (Figure 2). Finally, the patient underwent

Variables	ICT	SA
Age (Mean * SD)	70.5 ± 8.8	66.2 ± 15.8
Sex (Male : Female)	9 : 4	04:04
Laparoscopic Surgery	4	0
Complications	Wound Infection: 2	Wound Infection: 2
	Remnant Abscess: 2	Remnant Abscess: 2
	Femoral Nerve Palsy: 2	Femoral Nerve Palsy: 1
Hospital Stay (Day)	26.5 (11 - 96) (N = 9)*	22 (7 - 133) (N = 6)*
<b>Median and Range</b>		
Observation Period (Month)	5.2 (0.8 - 120) (N= 12)*	16.5 (0.4 - 36) (N = 7)*
<b>Median and Range</b>		
Depth of Tumor (SS : SE : SI)	04:06:03	04:06:04
Lymph Node Metastasis	6 : 4 (N = 10)*	4:3: 4(N=7)*
<b>(Positive : Negative)</b>		
Recurrence	Liver Metastasis: 1	Liver Metastasis: 1
	Peritoneal Dissemination: 2	Peritoneal Dissemination: 1
Cancer Death	2	1

\* Information about each factor was available in the indicated number of case reports

**Table 2:** Comparison between the cases treated with ICT and those with SA.

laparoscopic right hemicolectomy with lymph node dissection and closure of the mucus fistula. Although the rigid attachment of the cecum colon to the retroperitoneum and the major psoas muscle made the operation challenging, we managed to remove the cecum colon with a partial resection of the psoas muscle, as in the other two reported cases. Owing to its anatomical complexity, debridement of the abscess cavity was conducted instead of complete resection. Operative time was 4 hours 33 minutes with blood loss of 150 ml. The patient was discharged eight days after the surgery without any complications. Pathological examination of the resected specimen revealed subserosal invasion of the tumor with lymph nodes metastasis (ypT3 ypN1 cM0 ypStage IIIa, according to Japanese Classification of Colorectal Cancer 8th edition, and to some extent, the response of tumor to chemotherapy. It has been two months since the surgery, and no signs of recurrence have been observed.

## Discussion

Our institute only treated three cases of CRA from 2014 to 2016 while 372 patients underwent surgery for colorectal cancer during the same period, indicating the small proportion of colorectal cancer cases presenting as CRA. Based on a search of the Japan Medical Abstracts Society (<http://login.jamas.or.jp/> using the keywords, “iliopsoas abscess”, “retroperitoneal abscess” and “colon cancer”, we found eighteen full case reports between 2000 and 2016 [3,6-18]. The combination of those cases and our cases will be referred to as the reviewed cases. The average age of the reviewed cases was 69.1-years, and sex ratio was 13 men to 8 women. The median of CEA and CA19-9 was 14.0 ng/ml and 7.3 U/ml, respectively. The number of the reviewed cases with well-, moderately and poorly differentiated adenocarcinoma were eight, eight and one, respectively. There were also two cases of mucinous carcinoma reported, and two case reports did not provide histological data. Among the reviewed cases, 13 cases were treated with ICT and eight cases with surgery alone (SA as shown in Table 2. Comparing the cases treated with ICT to those treated with SA, it was seen that there were no significant differences in rates of postoperative complications, length of hospital stay following surgery, and cancer recurrence. Through our experience, however, we found that ICT can provide patient with benefits, such as an improvement of physical condition before surgery, lower risk of extensive surgery because of widespread

inflammation, and prevention of the discharge of pus into abdominal free space during surgery. In addition, laparoscopic surgery becomes feasible, as ICT reduces the amount of tissue affected by inflammation. Besides our three cases, there was another case in the ICT group which also underwent laparoscopic surgery (Table 2) [6]. Taken together, we assumed that ICT should be applied for the treatment of CRA in clinical practice.

It is difficult to discuss the prognosis of CRA, as the mean observation period of the reviewed cases after surgery was too short. Even within this short time period, five of the 21 cases did recur after surgery, suggesting CRA is likely to be associated with poorer outcomes compared to other colorectal cancer cases (Table 2). Of the five cases with recurrence, three cases had recurrence with peritoneal dissemination, suggesting that CRA is associated with a high risk for recurrence in this location. This raises questions about surgical procedures in the resection of CRA to prevent peritoneal dissemination and recurrence. When colon cancer invades an adjacent organ, en bloc resection of colon and invaded organ is generally recommended [19]. Therefore, en bloc resection including complete resection of the abscess cavity may also be recommended for CRA, but this is very challenging in real clinical practice because of the difficulties in identification of the surgical margin of an abscess cavity. En bloc resection could also lead to overextended surgery and increase the risk of postoperative complications such as femoral nerve palsy. In most reviewed cases, en bloc resection of the main tumor and invaded organs and the debridement of abscess cavity to the greatest extent possible was performed. Considering this, we assume that multimodal therapy, including chemotherapy and radiotherapy, both before and after surgery, is necessary for the treatment of CRA with extended follow-up of the patient.

## Conclusion

In conclusion, our experiences support the importance of ICT in the treatment of CRA. These patients appear to be at higher risk for cancer recurrence, particularly locally or with peritoneal involvement; however, complete en bloc resection of the abscess cavity is considered unreasonable. We need a larger study with a longer follow-up period to have more data on prognosis, recurrence rate and patterns, surgical procedures and adjuvant chemotherapy for CRA.

## Declarations

### Ethics approval and consent to participate

This study was approved by the institutional review board at Sakai City Medical Center.

### Consent for publication

Written informed consent was obtained from the patients for publication of this case report and any accompanying images. A copy of the written consent is available for review by the Editor-in-Chief of this journal

### Availability of data and material

The datasets analyzed during the current study are available from the corresponding author upon reasonable request.

### Competing interests

There are no potential conflicts of interest to disclose.

### Funding

None.

### Author contributions

G.S. wrote the manuscript. G.S., K.A. and K.N. designed the study. M.T., T.K., J.M., S.N., Y.M., J.F., and T.O. proofread the manuscript.

### Acknowledgements

None.

### References

- Peterson CM, Allison JG, Lu CC (1983) Psoas abscess resulting from perforating carcinoma of the sigmoid colon. Report of a case. *Dis Colon Rectum* 26: 390-392.
- Cacurri A, Cannata G, Trastulli S, Desiderio J, Mangia A, et al. (2014) A rare case of perforated descending colon cancer complicated with a fistula and abscess of left iliopsoas and ipsilateral obturator muscle. *Case Rep Surg* 2014: 128506.
- Ohta R, Takahashi Y, Kawahara Y, Kitamura M, Goto M, et al. (2009) A case of carcinoma of the ascending colon presented with an abscess in the right iliopsoas muscle. *J Jpn Surg Assoc* 70: 2072-2076.
- Welch JP, Donaldson GA (1974) Management of severe obstruction of the large bowel due to malignant disease. *Am J Surg* 127: 492-499.
- Matsui K, Tazawa K, Yoshida T, Shinbo M, Yamagishi F, et al. (2007) A Case of the Transverse Colon Cancer with Abdominal Wall Abscess. *Jpn J Gastroenterol Surg* 40: 656-660.
- Matsumoto H, Umakoshi K, Kojima Y, Satoshi K, Takeba J, et al. (2014) A Case of Thigh Gas Gangrene Resulting from the Penetration of Descending Colon Cancer. *J Abdom Emerg Med* 34: 741-745.
- Yoshimoto K, Yamasaki Y, Takeshita M, Kadoya N, Matsuki N (2012) A case of carcinoma of the descending colon presented with an abscess in the left iliopsoas muscle. *J Jpn Surg Assoc* 73: 2616-2620.
- Tokumou S, Nakamura S, Mizou T, Kubo T, Suzuka I, et al. (2011) A case of appendiceal carcinoma invading the colon diverticulum, and causing abscess of the iliopsoas muscle. *Journal of Clinical Surgery* 66: 1687-1690.
- Soeno M, Hirukawa H, Kobayashi T, Naito T, Matsuoka H, et al. (2011) Two Cases of Primary and Secondary Iliopsoas Muscle Abscess. *Niigata Med J* 125: 391-398.
- Okita A, Kubo Y, Tanada M, Kurita A, Takashima S (2007) Unusual Abscesses Associated with Colon Cancer: Report of Three Cases. *Acta Medica Okayama* 61: 107-113.
- Neduka H, Yoshizumi T, Saito M, Fujii H (2007) A Case of Primary Carcinoma of the Appendix Forming an Abscess in the Right Iliopsoas Muscle. *J Jpn Soc Coloproctol* 60: 467-470.
- Kitagawa N, Kuromizu J, Egami S, Okura M, Takahashi K, et al. (2007) A case of cecal carcinoma with retroperitoneal abscess. *JJCS* 32: 765-768.
- Tsukuda K, Ikeda E, Miyake T, Ishihama Y, Watatani H, et al. (2005) Abdominal wall and thigh abscess resulting from the penetration of ascending colon cancer. *Acta Medica Okayama* 59: 281-283.
- Nomura S, Nishida K, Furutani A (2005) A case of cecal cancer complicated with a right psoas abscess. *J Jpn Surg Assoc* 66: 111-114.
- Nakamori Y, Mizushima T, Ito T, Mizuno H, Soma Y, et al. (2005) A case of descending colon cancer complicated with a left psoas abscess. *Surgery* 67: 1351-1354.
- Asami S, Fukushige H, Itoh N, Sakamoto Y, Nagafuchi Y (2004) A case of descending colon cancer complicated with a left psoas abscess. *J Jpn Surg Assoc* 65:1323-1327.
- Sakai H, Sakai T, Kiyomatsu K, Yamamoto H (2003) A case of ascending colon cancer with an iliopsoas muscle abscess. *J Kurume Med Assoc* 66: 226-229.
- Naoko K, Oh Y, Sasaki H, Shimomatsuya T, Maruhashi K (2001) A case of colon cancer complicated with psoas abscess. *J Jpn Surg Assoc* 62: 2470-2473.
- McGlone TP, Bernie WA, Elliott DW (1982) Survival following extended operations for extracolonic invasion by colon cancer. *Arch Surg* 117: 595-599.

## OMICS International: Open Access Publication Benefits & Features

### Unique features:

- Increased global visibility of articles through worldwide distribution and indexing
- Showcasing recent research output in a timely and updated manner
- Special issues on the current trends of scientific research

### Special features:

- 700+ Open Access Journals
- 50,000+ editorial team
- Indexing at major indexing services
- Rapid review process
- Quality and quick editorial, review and publication processing
- Indexing at major indexing services
- Sharing Option: Social Networking Enabled
- Authors, Reviewers and Editors rewarded with online Scientific Credits
- Better discount for your subsequent articles

Submit your manuscript at: <http://www.omicsonline.org/submit/>

**Citation:** Sawada G, Nakata K, Tsujie M, Amano K, Mikami J, et al. (2017) Laparoscopic Colectomy for Colon Cancer with Retroperitoneal Abscess Treated with Initial Conservative Therapy: A Report of Three Cases with a Literature Review. *J Clin Case Rep* 7: 975. doi: [10.4172/2165-7920.1000975](https://doi.org/10.4172/2165-7920.1000975)