

Loupe Assisted Thyroidectomy: Prevention of Complications is better than Treating Them

Mohamed Lotfy Ali^{*}, Mostafa Mohamed Khairy and Fady Fayek

General Surgery Department, Zagazig University, Zagazig, Egypt

^{*}Corresponding author: Mohamed Lotfy Ali, MD, General Surgery Department, Zagazig University, Zagazig, Egypt, Tel: +201060140862; E-mail: lotfymira@yahoo.com

Received date: March 26, 2017; Accepted date: April 10, 2017; Published date: April 15, 2017

Copyright: © 2017 Ali ML, et al. This is an open-access article distributed under the terms of the Creative Commons Attribution License, which permits unrestricted use, distribution, and reproduction in any medium, provided the original author and source are credited.

Abstract

Aim: Studying the value of the surgical loupe in the enhancement of performing safe thyroidectomy via dissection of the major structures which are vulnerable to injury during the operation.

Subjects and methods: 150 patients with benign and malignant thyroid masses underwent near total or total thyroidectomy at Zagazig university hospitals. History taking and all necessary investigations were done. Thyroidectomy was done under the magnification of the surgical loupe and we dissected the recurrent laryngeal nerve, the external branch of superior laryngeal nerve, branches of superior thyroid artery and selectively ligating them and trace the parathyroid glands by following their minute blood vessels originating from the inferior thyroid artery.

Results: Mean age of the patients was 42.5 years (range: 23-69). Female: male ratio was 19:11 (95/55). 65 patients (43.3%) had a discrete thyroid nodule and 85 patients (56.7%) had multinodular goiter. Patients were sent home in a mean of 1.6 days (1-4 days). No operative related mortality was encountered. Only three cases of transient hypocalcaemia which were resolved within three days by oral calcium supplementation and symptoms did not recur during the follow-up of these three patients. All patients were extubated without any complications. There was no any case recorded for hoarseness of voice or low pitched voice. There was only one case of secondary hemorrhage and was re-explored for control of the source (injured anterior jugular vein on the right side). Three cases developed hypertrophic scars during the follow up.

Conclusion: total or near total thyroidectomy can be done with a minimal number of complications by using the surgical loupe during the dissection of the recurrent laryngeal nerve, the external branch of the superior laryngeal nerve and the parathyroid glands and their minute blood vessels.

Keywords: Surgical loupe; Thyroidectomy; Complications

Introduction

Pathology of the thyroid gland is considered as the 2nd most frequent endocrine disease coming after diabetes mellitus [1]. Thyroidectomy is one of the most common general surgical operations performed in areas of iodine deficiency [2,3]. The chief postoperative morbidities of thyroidectomy are unilateral or bilateral injury of recurrent laryngeal nerve, hypoparathyroidism and injury of superior laryngeal nerve [4-6]. It is well known that the recurrent laryngeal nerve injury is of low incidence, however, when it does occur it will lead to a distressing life-long handicap, so we would better avoid injuring it rather than managing the patient after becoming handicapped [7].

Post-thyroidectomy hypocalcaemia is another major lifelong morbidity to the patients. The most common preventable cause of hypoparathyroidism is iatrogenic due to ignorance of the anatomic field [7-11].

Injury of the superior laryngeal nerve during thyroidectomy is another lifelong handicapping complication of thyroidectomy,

especially for those whose job requires an excellent voice to be achieved. [7]

Any of these three complications have a more distressing effect on patient's life than the thyroid pathology itself with exclusion of thyroid cancer, so in this study, we aimed to focus on our experience to avoid these handicapping complications, namely, recurrent laryngeal nerve injury, hypoparathyroidism and superior laryngeal nerve injury.

Methods

Between February 2014 and January 2017, 150 patients with benign and malignant thyroid mass underwent near total or total thyroidectomy at Zagazig university hospitals. All patients were subjected to history taking, clinical examination, laboratory investigations including preoperative and postoperative ionized calcium level, neck ultrasound was done for every patient, neck CT scan for patients when there is a doubt of retrosternal extension or malignancy, indirect laryngoscopy was done preoperatively for every patient for vocal cords assessment and Patients with solitary thyroid nodules were submitted to (FNAC) fine needle aspiration cytology.

Operations were done by a senior staff of general surgery under general anesthesia.

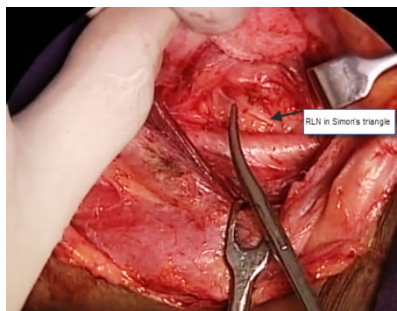


Figure 1: RLN in simons triangle.



Figure 2: The loupe.

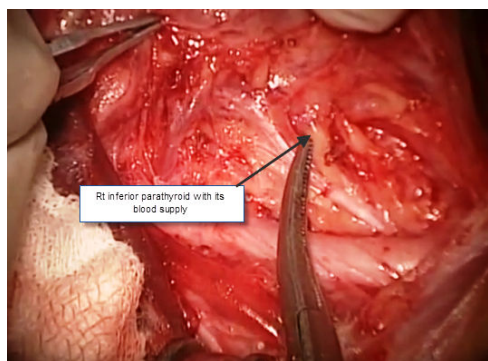


Figure 3: Inferior parathyroid.

Ordinary neck Kocher incision, near total or total thyroidectomy was done in the following manner using bipolar diathermy, [dissection of the thyroid lobe from the strap muscles till the tracheo-esophageal groove, ligation of middle thyroid vein if present, the recurrent laryngeal nerve with its all possible branches, was searched for in the triangle of Simon (which is bounded by the esophagus medially, common carotid artery laterally and the inferior thyroid artery superiorly) Figure 1, searched for the parathyroid glands using a 25x magnifying loupe (Aomekie®, 9892G) Figure 2 to trace the small branches of inferior thyroid artery supplying each of them and preserved these branches as well as the glands themselves Figure 3, then we attacked the upper pole of the lobe using the loupe and

dissected the external branch of the superior laryngeal nerve with selective ligation of superior thyroid vessels and not ligating the whole upper pole of the lobe as was usually practiced and lastly attacked the lower pole and dissected the lobe from the trachea Figures 4 and 5, soft drain was inserted and the wound was closed in layers]. The retrieved specimens were inspected for the presence of parathyroids and sent for histopathological examination.

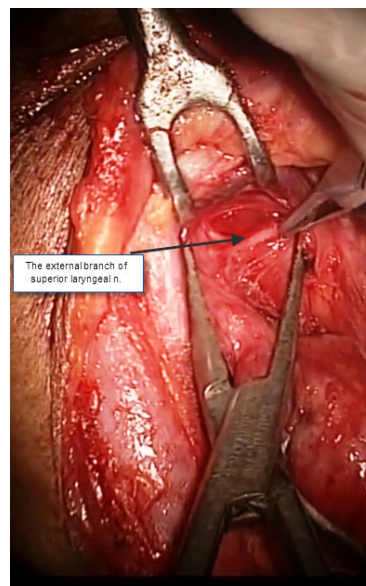


Figure 4: External branch of superior laryngeal n.

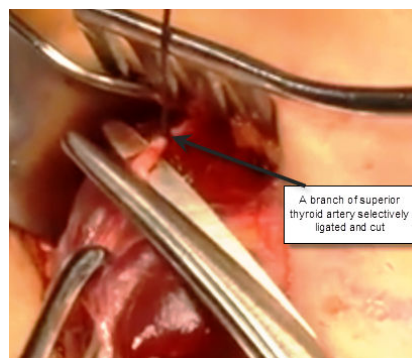


Figure 5: A branch of superior thyroid artery.

Results

Mean age of the patients was 42.5 years (range: 23-69). Female: male ratio was 19:11 (95/55) (Table 1). Of the 150 cases of thyroid swelling, 65 patients (43.3%) had a discrete thyroid nodule and 85 patients (56.7%) had multinodular goiter. On histopathology (Table 2), 125 (83.3%) patients had a benign pathology and 25 patients (16.7%) had a malignant pathology. Of those 25 cases who had a malignant pathology, 13 cases (52%) had papillary carcinoma, 12 cases (48%) had follicular carcinoma. Patients were sent home in a mean of 1.6 days (1-4 days). No operative related mortality was encountered. Only three

cases of transient hypocalcaemia which was resolved within three days by oral calcium supplementation and symptoms did not recur during the follow-up of those three patients. All patients were extubated (after assessment of the vocal cord position and mobility by the anesthetist) in the operating room without any complications. There was no any case recorded for hoarseness of voice or low pitched voice. There was only one case of secondary hemorrhage and was re-explored to control the source (injured anterior jugular vein on the right side). Three cases developed hypertrophic scars during the follow up (Table 3).

Demographic data	Results
Age	Median=42.32 (range: 23-69 years)
Sex (female : male)	19:11 (95/55)

Table 1: Demographic data.

Histopathology	Results	
Benign	125 (83.3%)	
Malignant	25 (16.7%)	
	Papillary	follicular
	13 (52%)	12 (48%)

Table 2: Histopathology of retrieved thyroid.

Complications	Results
Operative mortality	0 (0%)
Recurrent laryngeal n. injury	0 (0%)
Postoperative hypocalcaemia	3 (0.02%) transient
Postoperative voice affection	0 (0%)
Bleeding (secondary)	1 (0.007%)
Hypertrophic scars	3 (0.02%)
Mean operative time	115.7 minutes (range=95-150 min.)

Table 3: Complication results.

Discussion

Surgical removal of the thyroid gland is the most frequent endocrine surgical operation. Recent management principals of thyroid diseases had been started in the beginning of the nineteenth century and it is still developing till recently when numerous diverse techniques were added to the surgical performance [12-14]. Thyroidectomy aims at removing the gland with preservation of the recurrent laryngeal nerve, superior laryngeal nerve and parathyroid glands with the least amount of blood loss. Surgical removal of the thyroid has a very low complications rate, if it is performed by a proficient surgeon[13-15].Thyroid surgery complications are directly connected to the pathology, size of the gland, the skills of the surgeon and the use of careful dissection in these dangerous areas [16,17]. If the surgeon pays a particular awareness to these dangerous areas, the morbidities can be minimized.

In this study, the mean operative time for the cases was 115.7 minutes which is somewhat longer than the average operative time in several studies however, this did not have a passive effect on the patients in the postoperative period [18].

One of the most important morbidities of thyroidectomy is recurrent laryngeal nerve injury caused by iatrogenic damage during the operation. Its injury incidence ranges from zero to 5.8% [17,19-22]. In our study, no single case of recurrent laryngeal nerve injury was documented as we made all the efforts to dissect it starting at Simon's triangle till its insertion into the larynx with preservation of all its branches making use of the surgical loupe (Aomekie, 9892G) with a magnification power of 25 times and we used the bipolar diathermy for hemostasis. The exposure itself might increase the rate of complication resulting from the mechanical injury or inadequate nutrition [17] however, this did not occur in any of our patients.

Another important complication of thyroidectomy is the injury to the external branch of the superior laryngeal nerve which is thought to be less important than RLN injury. However, injury of the external branch of the superior laryngeal nerve after thyroid surgery is frequent, but ignored. Its incidence ranges from 0 to 58% [16,23-26]. The big difference in results is due to overlooking of this type of injury. There are different studies which were concerned about this type of injury some suggested dissection of the external branch and some advocated selective ligation of the superior thyroid vessels [16,24,25,27]. However we think that both strategies are important and should be combined with each other. This explains why we did not meet such complication in any of our patients.

The most common and most horrible complication of thyroidectomy is the permanent hypocalcaemia. Its incidence ranges from 0.3-65% in several studies [28-31]. Parathyroid glands are supplied by minute branches of the inferior thyroid artery and we consider these vessels as the most evident proof of their location. Injury to these vessels is the causing factor of the permanent hypocalcaemia even though the glands were not removed during surgery. In our study we used the surgical loupe to identify these minute vessels a preserved them for each gland and we got only three cases of hypocalcaemia which was transient and resolved completely within three days of oral calcium supplements.

The advantage of using the magnification ability of the loupe during thyroidectomy is better visualization of the recurrent laryngeal nerve, the parathyroids and the external branch of the superior laryngeal nerve and hence decreasing the incidence of their injury. However the drawbacks of using the loupe during thyroidectomy are slight increase in the operative time, the cost of the loupe and the surgeon should have some easily gained psychomotor experience in operating in a magnified field.

The surgical loupe used in this study is not expensive and costs around twenty US Dollars including the shipping fees.

In conclusion, total or near total thyroidectomy can be done with a minimal number of complications by using the surgical loupe during the dissection of the recurrent laryngeal nerve, the external branch of the superior laryngeal nerve and the parathyroid glands and their minute blood vessels. We advise general surgery colleagues to follow the strategy we used during thyroidectomy and to make use of the surgical loupe in such operations.

References

1. Tunbridge WM, Evered DC, Hall R, Appleton D, Brewis M, et al. (1997) The spectrum of thyroid disease in a community: the Wickham survey. *Clin Endocrinol* 77: 481-493.
2. Bellantone R, Lombardi CP, Bossola M, Boscherini M, De Crea C, et al. (2002) Total thyroidectomy for management of benign thyroid disease: review of 526 cases. *World J Surg* 26: 1468-1471.
3. Bron LP, O'Brien CJ (2004) Total thyroidectomy for clinically benign disease of thyroid gland. *Br J Surg* 91: 569-574.
4. Kocher T (1874) To the pathology and therapy of the goiter. *Dtsch Z Chir* 4: 417.
5. Halsted WS (1920) The operative story of goiter: the author's operation. *Johns Hopkins Rep* 19: 71.
6. De Quervain F (1912) On the technique of goiter surgery. *Dtsch Z Chir* 116: 574.
7. Moulton-Barrett R, Crumley R, Jalilie S, Segina D, Allison G, et al. (1997) Complications of thyroid surgery. *Int Surg* 82: 63-66.
8. Reeve T, Thompson NW (2000) Complications of Thyroid Surgery: How to Avoid Them, How to Manage Them, and Observations on Their Possible Effect on the Whole Patient. *World J Surg* 24: 971-975.
9. Michie W, Duncan T, Hamer-Hodges DW (1971) Mechanisms of hypocalcaemia after thyroidectomy for thyrotoxicosis. *Lancet* 297: 508-514.
10. McHenry CR, Speroff T, Wintworth D, Murphy T (1994) Risk factors for postthyroidectomy hypocalcaemia. *Surgery* 116: 641-648.
11. Wingert DO, Friesen SR, Iliopoulos GI, Pierce GE, Thomas JH, et al. (1986) Post-thyroidectomy hypocalcaemia. Incidence and risk factors. *Am J Surg* 152: 606-609.
12. Miccoli P (2002) Minimally invasive surgery of thyroid and parathyroid diseases. *Surg Endosc* 16: 3-6.
13. Ikeda Y, Takami H, Tajima G, Sasaki Y, Takayama J, et al. (2002) Direct mini-incision thyroidectomy. *Biomed Pharmacother* 56: 60-63.
14. Raul A, Todd M, Stan B, Sidhu M, Leigh W, et al. (2008) Minimally invasive thyroid surgery for single nodules: An evidence-based review of the lateral mini-incision technique. *World J Surg* 32: 1341-1348.
15. Sgourakis G, Sotiropoulos GC, Neuhauser M (2008) Comparison between minimally invasive video-assisted thyroidectomy and conventional thyroidectomy: is there any evidence-based information? *Thyroid* 18: 721-727.
16. Lennquist S, Cahlin C, Smeds S (1987) The superior laryngeal nerve in thyroid surgery. *Surgery* 1102: 999-1008.
17. Steurer M, Pasler C, Denk DM, Schneider B, Niederle B, et al. (2002) Advantages of RLN identification in thyroidectomy and the importance of preoperative and postoperative laryngoscopic examination in more than 1,000 nerves at risk. *Laryngoscope* 112: 124-133.
18. Peter C, Silvia B, Wolfram T, Alexander R (2014) Prolonged duration of surgery is not a risk factor for postoperative complications in patients undergoing total thyroidectomy: a single center experience in 305 patients. *Patient Safety in Surgery* 8: 45.
19. Bhattacharyya N, Fried MP (2002) Assessment of the morbidity and complications of total thyroidectomy. *Arch Otolaryngol Head Neck Surg* 128: 389-392.
20. Jatzko GR, Lisorg PH, Muller MG, Vette VM (1994) Recurrent nerve palsy after thyroid operations-principal nerve identification and a literature review. *Surgery* 115: 139-144.
21. Lo CY, Kwok KF, Yuen PW (2000) A prospective evaluation of RLN paralysis during thyroidectomy. *Arch Surg* 135: 204-207.
22. Misiolek M, Waler J, Namyslowski G, Kuchorzewski M, Podwinski A, et al. (2001) Recurrent laryngeal nerve palsy after thyroid surgery: a laryngological and surgical problem. *Eur Arch Otorhinolaryngol* 258: 460-462.
23. Aluffi P, Policarpo M, Cherovac C, Olina M, Dosdegani R, et al. (2001) Post-thyroidectomy superior laryngeal nerve injury. *Eur Arch Otorhinolaryngol* 258: 451-454.
24. Bellantone R, Boscherini M, Lombardi CP, Bossola M, De Crea C, et al. (2001) Is identification of EBSLN mandatory in thyroid operation? Results of a prospective randomized study. *Surgery* 130: 1055-1059.
25. Cernea CR, Ferraz AR, Furlani J, Monteiro S, Nishio S, et al. (1992) Identification of the EBSLN during thyroidectomy. *Am J Surg* 164: 634-639.
26. Jansson S, Tisell LE, Hange I, Sanner E, Stenborg R, et al. (1988) Partial superior laryngeal nerve lesions before and after thyroid surgery. *World J Surg* 12: 522-527.
27. Friedman M, LoSavio P, Ibrahim H (2002) Superior laryngeal nerve identification and preservation in thyroidectomy. *Arch Otolaryngol Head Neck Surg* 128: 296-303.
28. Attie JN, Khafif RA (1975) Preservation of parathyroid glands during total thyroidectomy: improved technique utilizing microsurgery. *Am J Surg* 130: 399-404.
29. Herranz-Gonzalez J, Gavilan J, Matinez-Vidal J, Gavilan C (1991) Complications following thyroid surgery. *Arch Otolaryngol Head Neck Surg* 117: 516-518.
30. Mittendorf EA, McHenry CR (2001) Thyroidectomy for selected patients with thyrotoxicosis. *Arch Otolaryngol Head Neck Surg* 127: 61-65.
31. Shaha AR, Jaffe BM (1998) Parathyroid preservation during thyroid surgery. *Am J Otolaryngol* 19: 113-117.