

Rare Subcutaneous Localization of Leiomyoma: A Case Report

Kenza Oqbani^{1*}, Abdelmounim Mounni², Nawal Harchichi², Mariame Chraibi¹ and Sanae Abbaoui¹

¹Department of Pathology, Mohammed 1st University, Mohammed VI University Hospital, Oujda, Morocco

²Department of Pathology, Al Farabi Hospital, Oujda, Morocco

Abstract

A 55-year-old Arabic and Moroccan male patient presented with a painful nodule in the left knee without a previous history or trauma. The patient underwent a wide excision of the nodule. The histological study evoked the diagnosis of a subcutaneous leiomyoma. The final diagnosis was established by the immunohistochemistry. One year after the operation no tumor recurrence has been detected. Leiomyomas are benign soft tissue tumours, which occur most commonly in the skin of the lower extremities in middle-aged females. The main differential diagnosis is the leiomyosarcoma, hence the necessity of an extensive sampling of the lesion.

Keywords: Leiomyoma; Knee; Histology; Differential diagnosis; Immunohistochemistry

Background

Leiomyoma of the soft tissue is quite uncommon benign tumor accounting for less than 2% of all benign soft-tissue tumors [1]. It derives from smooth muscle cells. We distinguish deep and superficial forms. The deep form may rarely occur in the deep soft tissue of the extremities in adults. However, the knee affection remains exceptional and only a minority of cases has been reported [2,3]. Among superficial leiomyoma, there is cutaneous leiomyoma and vascular leiomyoma. Cutaneous leiomyoma commonly arises at the extremities, the trunk and the cervicofacial regions. Leiomyomas are treated curatively with resection.

Through this observation, we underline clinicopathological, therapeutic and evolutive features of this rare localization of leiomyoma.

Case Report

A 55-year-old Arabic and Moroccan male patient noticed a spontaneously painful nodule in his left knee swelling about 3 years before he was first diagnosed. The pain had been sporadic and vague at the onset, 18 months before the presentation. There was no history of a trauma, and apart from his knee problems, his past medical history was uneventful and his physical activities were kept.

On physical examination, the tumour presented as a subcutaneous whitish nodule at the anteromedial aspect of the left knee. It was tender to palpation and measured 15 mm in diameter. It was stiff-elastic, movable from the surrounding tissue and did not pulsate. There were no signs of a deep vein thrombosis and no intraarticular effusion. Compared to the controlateral side, the range of motion of his right

knee joint was normal. No radiographic examinations have been performed. The patient underwent wide excision of the nodule.

The macroscopic examination revealed a well circumscribed, homogeneous, firm and whitish nodule measuring 15 × 8 × 4 mm. Histological sections were prepared in the conventional manner and stained with haematoxylin and eosin. Histological examination showed a benign tumoral proliferation composed of intersecting fascicles of spindle cells (Figure 1a). These cells were characterized by an abundant eosinophilic cytoplasm and a regular, uniform, blunt-ended and cigar-shaped nuclei (Figure 1b). Cytonuclear atypias, mitosis and tumoral necrosis were absent (Figure 1b). There was no vascular proliferation and no hyaline or myxoid degenerations. The diagnosis of leiomyoma was held. A manual immunohistochemistry technique was made according to the enzymatic method employing the peroxidase and requiring a polymer. A panel of epithelial membrane antigen (EMA), smooth muscle actin (SMA), CD 68 and S-100 protein antibodies was applied to sections.

The immunohistochemistry confirmed the smooth muscular nature of tumoral cells by a strong staining with the smooth muscle actin antibody (Figure 2a) and a negative reaction against CD 68, S-100 protein (Figure 2b) and epithelial membrane antigen. Postoperatively, the patient experienced a complete and immediate resolution of his symptoms. One year after the operation, no tumor recurrence has been detected.

Discussion

Leiomyomas were described the first-time Stout [4]. There are two different types of leiomyoma; gynaecologic and non-gynaecologic type. The former interests abdominal cavity, lesser pelvis and retroperitoneum. The latter may be subdivided into subcutaneous (superficial) tissue and deep soft tissues of members, trunk, head and neck. The superficial leiomyoma of members affects commonly the lower extremities in 75% of cases than the upper extremities but

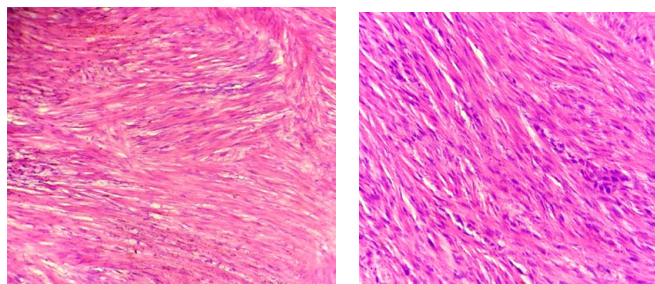


Figure 1: Leiomyoma: (a) Benign fasciculated smooth muscle proliferation, arranged in orderly intersecting fascicles (H&E Ex 200). (b) Abundant eosinophilic cytoplasm and regular, blunt-ended nuclei. Note the absence of atypia and mitotic activity (H&E Ex 400).

*Corresponding author: Oqbani Kenza, Department of Pathology, Mohammed 1st University, Mohammed VI University Hospital, Oujda, Morocco, Tel: 00212 661685466; E-mail: kenzaqbani@gmail.com

Received November 12, 2016; Accepted December 17, 2016; Published December 23, 2016

Citation: Kenza O, Abdelmounim M, Nawal H, Mariame C, Sanae A (2016) Rare Subcutaneous Localization of Leiomyoma: A Case Report. J Clin Case Rep 6: 903. doi: 10.4172/2165-7920.1000903

Copyright: © 2016 Oqbani K, et al. This is an open-access article distributed under the terms of the Creative Commons Attribution License, which permits unrestricted use, distribution, and reproduction in any medium, provided the original author and source are credited.

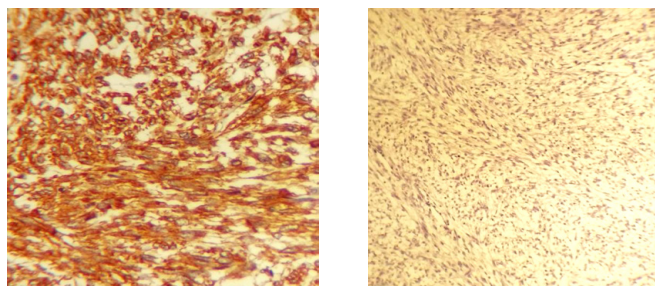


Figure 2: Immunohistochemistry: (a) Positive staining with anti-smooth muscle actin (SMA) (H&Ex 400). (b) Negative staining with anti-S100 protein (H&Ex 200).

rarely the knee [5]. We are aware of only a minority of cases of knee leiomyoma have been reported. The deep leiomyoma of member muscles is exceptional. This lesion is often isolated and painless.

The cutaneous or superficial localization has for origin the hair retractor muscles (3/4 of cases), particularly, on the zones of members extension. It can also derive from the deep dermis smooth muscles. However, the superficial leiomyoma (SL) can be multifocal interesting several cutaneous zones. In the majority of cases, it arises at the teenager or younger adult and it is more prevalent in woman [5]. The peak of incidence is between the fourth and the sixth decade of life [5].

Pain and/or tenderness are the most characteristic complaint in 60% to 75% of patients. The lesion is often whitish and small-sized papules ranging from 1 cm to 2 cm [5]. It may present some myxoid degenerations or be calcified. In this case, it may be detected radiographically. The exact localization and morphology of the leiomyoma were well demonstrated on magnetic resonance imaging (MRI). In accordance with other reports [6], the leiomyoma was characterized by well-defined margins and a marked, peripheral contrast enhancement.

Macroscopically, SL realizes red or brown papules, sometimes small-sized nodules. In contrary, deep leiomyoma is grey-whitish and well demarcated having a size ranging from 2.5 cm to 3.7 cm.

Histologically, the cutaneous leiomyoma is well-demarcated dermal proliferation, separated from the epidermis by a safe area. It is composed of interlacing bundles of smooth muscle cells. It is defined by tumour with no cytological pleomorphism, no tumour cell necrosis, a mitotic rate less than one per 50 high-power fields.

These criteria must be combined to eliminate the diagnosis of a leiomyosarcoma hence the interest of an extensive sampling of the lesion. The immunohistochemical workup would typically require not only confirmation of the smooth-muscle differentiation, using smooth muscle actin but also exclusion of others differential diagnosis especially histiocytofibroma and benign schwannoma by a negative staining for respectively CD68 and S100 protein.

Leiomyomas of soft tissue should be cured by complete excision. If they recur, the recurrence should be non-destructive. Long-term follow-up did not reveal metastases, but one of 29 patients reported by Billings et al. [7] and two of 36 patients reported by Paal and Miettinen [8] had local recurrence. However, none of the patients with recurrence demonstrated disease progression in follow-up.

Conclusions

Leiomyomas are a very rare tumor, it has to be considered in the differential diagnosis for painful swellings of the lower extremities. The complete surgical excision enables a histopathologic diagnosis and offers complete relief of symptoms as shown by this case. The rate of local recurrence is very low with complete excision. However, if a tumour does recur one must consider leiomyosarcoma as a probable diagnosis.

References

1. DeMouy EH, Kaneko K, Rodriguez RP (1995) Calcified soft tissue leiomyoma of the shoulder mimicking a chondrogenic tumor. *Clin Imaging* 19: 4-7.
2. Dicaprio MR, Jokl P (2003) Vascular leiomyoma presenting as medial joint line pain of the knee. *Arthroscopy* Mar 19: E24.
3. Murty AN, Ireland J (2000) Angiomyoma of the patellar fat pad. *Knee* 7: 253-254.
4. Stout AP (1937) Solitary cutaneous and subcutaneous leiomyoma. *Am J Cancer* 29: 435-469.
5. Hachisuga T, Hashimoto H, Enjoji M (1984) Angioleiomyoma: A clinicopathologic reappraisal of 562 cases. *Cancer* 54:126-130.
6. Gebhardt MC, Ready JE, Mankin HJ (1990) Tumors about the knee in children. *Clin Orthop* 255: 86-110.
7. Billings SD, Folpe AL, Weiss SW (2001) Do leiomyomas of deep soft tissue exist? An analysis of highly differentiated smooth muscle tumors of deep soft tissue supporting two distinct subtypes. *Am J Surg Pathol* 25: 1134-1142.
8. Paal E, Miettinen M (2001) Retroperitoneal leiomyomas: A clinicopathologic and immunohistochemical study of 56 cases with a comparison to retroperitoneal leiomyosarcomas. *Am J Surg Pathol* 25: 1355-1363.

Citation: Kenza O, Abdelmounim M, Nawal H, Mariame C, Sanae A (2016) Rare Subcutaneous Localization of Leiomyoma: A Case Report. J Clin Case Rep 6: 903. doi: [10.4172/2165-7920.1000903](https://doi.org/10.4172/2165-7920.1000903)

OMICS International: Open Access Publication Benefits & Features

Unique features:

- Increased global visibility of articles through worldwide distribution and indexing
- Showcasing recent research output in a timely and updated manner
- Special issues on the current trends of scientific research

Special features:

- 700+ Open Access Journals
- 50,000+ editorial team
- Indexing at major indexing services
- Rapid review process
- Quality and quick editorial, review and publication processing
- Indexing at major indexing services
- Sharing Option: Social Networking Enabled
- Authors, Reviewers and Editors rewarded with online Scientific Credits
- Better discount for your subsequent articles

Submit your manuscript at: <http://www.omicsonline.org/submission/>