

## Split-Night CPAP Therapy for OSA to Improve Joint Immobility

Prosenjit Dutta<sup>1</sup> and Sophie West<sup>2\*</sup>

<sup>1</sup>Consultant, Respiratory medicine, Sunderland Royal Hospital, Sunderland, SR4 7TP, UK

<sup>2</sup>Consultant, Newcastle Regional Sleep Service, Newcastle upon Tyne Hospitals NHS Foundation Trust, NE7 7DN, UK

### Abstract

A 47-year-old woman presented to clinic with exertional breathlessness, snoring, choking, witnessed apnoeas and daytime somnolence. Past history included Idiopathic Juvenile Arthritis, diagnosed at age 8, since when she had been taking prednisolone. Her sleep study identified severe Obstructive Sleep Apnoea (OSA).

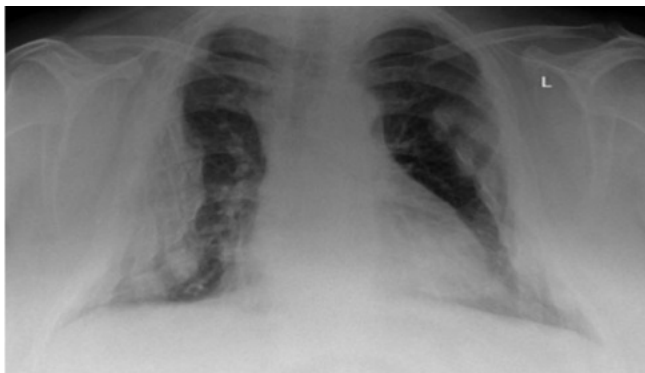
She was commenced on Continuous Positive Airway Pressure (CPAP) therapy, which improved her sleep quality so much that she hardly moved at night and consequently woke up with early morning joint stiffness. She therefore limited her CPAP use and her symptoms persisted. Over time she developed a regime of split-night CPAP use that improved her OSA-related symptoms and joint discomfort.

**Keywords:** Obstructive sleep apnoea; Idiopathic juvenile arthritis; CPAP; Joint immobility

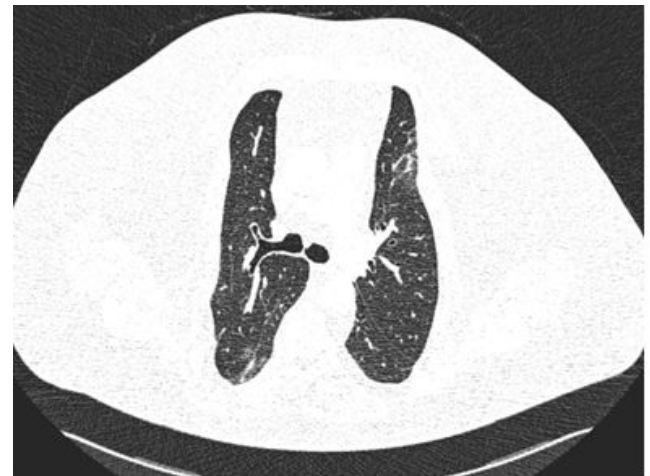### Case Report

A 47-year-old woman presented to the Sleep clinic with exertional breathlessness, snoring, choking, witnessed apnoeas and daytime somnolence. Past history included Idiopathic Juvenile Arthritis, diagnosed at age 8, since when she had been taking prednisolone. Her body mass index was 29 kg/m<sup>2</sup> and Epworth Sleepiness Score (ESS) 21/24. She had a small pharynx on direct inspection. Chest radiograph (Figure 1) and CT scan chest (Figure 2) showed significant chest wall deformity secondary to multiple osteoporotic rib fractures, presumably from long-term corticosteroids. Lung function showed a restrictive defect with reduced lung volumes. Sleep study (Figure 3 and Table 1) identified severe Obstructive Sleep Apnoea (OSA) with 4% oxygen desaturation index (ODI) of 165/hr with blood gas of pH 7.36, pO<sub>2</sub> 8.7, pCO<sub>2</sub> 6.3, bicarbonate 26, due to a combination of OSA, weight and chest wall deformity. The OSA was likely to be caused by her excess weight and small pharynx.

She was commenced on Continuous Positive Airway Pressure (CPAP) therapy for OSA, fixed pressure 10 cm H<sub>2</sub>O. This improved her sleep quality so much, she hardly moved over night and consequently awoke with significant early morning joint stiffness, from which she took hours during the daytime to recover. She therefore limited CPAP use (average 0.3hr/night); her symptoms persisted and ESS remained 21.



**Figure 1:** Chest X-ray showing chest wall deformity secondary to osteoporotic multiple rib fractures (patient consent obtained for all images).



**Figure 2:** CT scan chest confirming significant chest wall deformity secondary to multiple rib fractures compounded by increased BMI, both secondary to long-term corticosteroid therapy.

Autoset CPAP was then tried to see if its variable pressure caused more arousals, allowing increased movement during the night; it did not. She also tried an alarm waking her every 90 minutes or 4 hourly intervals, to allow stretching of her joints, but she found it difficult to get back to sleep. Over time, she developed a regime of split night CPAP use: using CPAP between 1:00- 2:00 am and then again from 6:00 am in the morning to achieve an average compliance of 3.6 hours/night. This has improved her OSA-related symptoms as well as the joint discomfort caused by overnight immobility. Investigations performed with this split night CPAP regime showed improved ESS (5) and ODI, 16/hour

**\*Corresponding author:** Sophie West, Consultant, Newcastle Regional Sleep Service, Newcastle upon Tyne Hospitals NHS Foundation Trust, NE7 7DN, UK, Tel: +441912085851; E-mail: [Sophie.west@nuth.nhs.uk](mailto:Sophie.west@nuth.nhs.uk)

Received July 13, 2017; Accepted July 16, 2017; Published July 24, 2017

**Citation:** Dutta P, West S (2017) Split-Night CPAP Therapy for OSA to Improve Joint Immobility. J Sleep Disord Ther 6: 274 doi: [10.4172/2167-0277.1000274](https://doi.org/10.4172/2167-0277.1000274)

**Copyright:** © 2017 Dutta P, et al. This is an open-access article distributed under the terms of the Creative Commons Attribution License, which permits unrestricted use, distribution, and reproduction in any medium, provided the original author and source are credited.

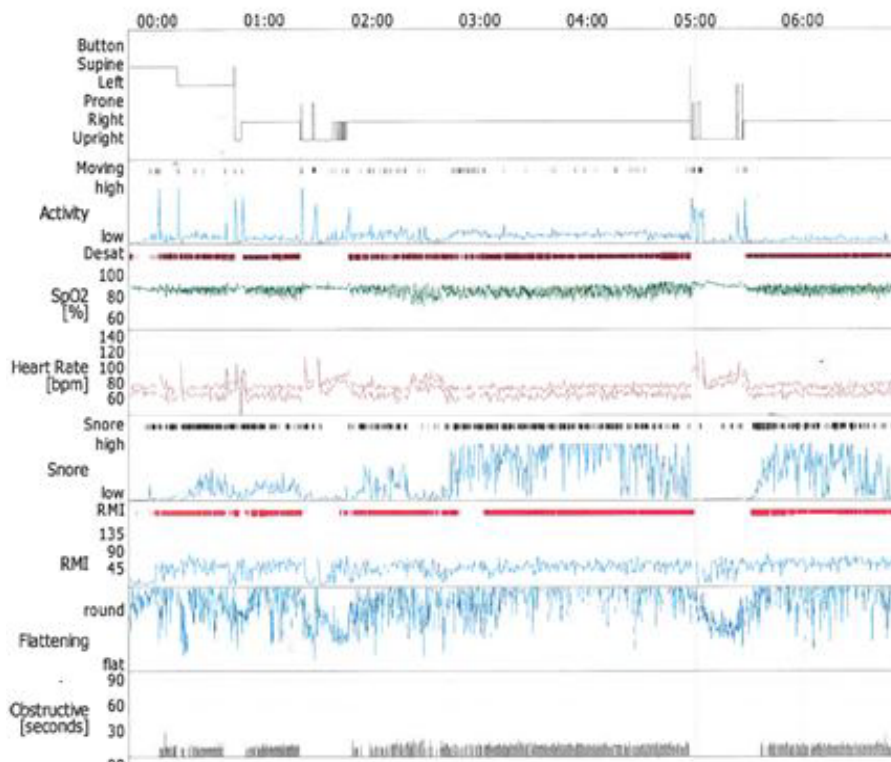


Figure 3: Summary graph of the sleep study (Pre CPAP therapy) of the patient showing oxygen desaturation index of 165/hour, mean oxygen saturation 86%.

Desaturation Fall	Number	Cumulative Number	OD/h	Cumulative OD/H
Total	991	991	165.5	165.5
<5%	77	991	12.9	165.5
5%-9%	459	914	76.7	152.7
10%-20%	452	455	75.5	76.0
>20%	3	3	0.5	0.5

Table 1: Oxygen desaturation index of 165/hour, mean oxygen saturation 86%.

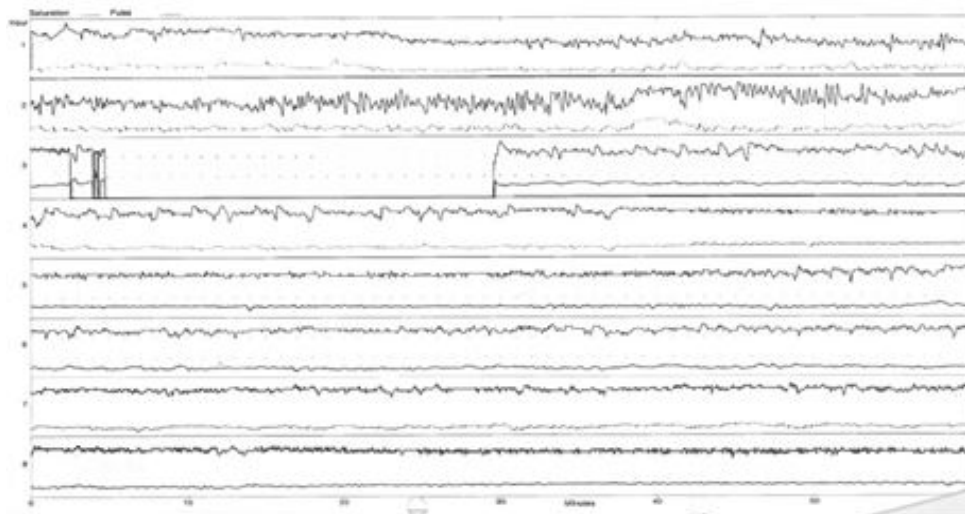


Figure 4: Pulse oximetry of the same patient using split night CPAP. Oxygen Desaturation Index is improved to 16/hour, mean oxygen saturation of 92%. The time when CPAP is not used in hours 2, 3 and 4 is clearly seen.

(Figure 4). There are no case reports of similar CPAP limitations due to joint problems. One report describes a 10 year old with arthrogryposis and OSA, but does not mention similar CPAP issues [1]. Split-night diagnostic -CPAP titration studies have been described previously, but not split-night CPAP therapy [2]. This novel approach may be useful in patients with joint stiffness caused by immobility in deep sleep with CPAP [3].

## Conclusion

Some patients with arthritis may find their joints are stiff from overnight immobility when they use CPAP successfully for the treatment of OSA. It may be helpful for these people to use split- night

CPAP therapy as a way of partially treating OSA and allowing some nocturnal joint movement.

## References

1. Jon C, Mosquera RA, Mitchell S, Mazur LJ (2014) Obstructive sleep apnoea and arthrogryposis. *BMJ Case Rep*.
2. Kushida CA, Michael LR, Hirshkowitz M, Morgenthaler LT, Alessi AC, et al. (2006) American Academy of Sleep Medicine. Practice parameters for the use of continuous and bi-level positive airway pressure devices to treat adult patients with sleep-related breathing disorders. *Sleep* 29: 375-380.
3. Rossi VA, Schwarz EI, Bloch KE, Stradling JR, Kohler M (2014) Is continuous positive airway pressure necessarily an everyday therapy in patients with obstructive sleep apnoea? *Eur Respir J* 43: 1387-1393.

Citation: Dutta P, West S (2017) Split-Night CPAP Therapy for OSA to Improve Joint Immobility. J Sleep Disord Ther 6: 274 doi: [10.4172/2167-0277.1000274](https://doi.org/10.4172/2167-0277.1000274)

## OMICS International: Open Access Publication Benefits & Features

### Unique features:

- Increased global visibility of articles through worldwide distribution and indexing
- Showcasing recent research output in a timely and updated manner
- Special issues on the current trends of scientific research

### Special features:

- 700+ Open Access Journals
- 50,000+ editorial team
- Rapid review process
- Quality and quick editorial, review and publication processing
- Indexing at PubMed (partial), Scopus, DOAJ, EBSCO, Index Copernicus and Google Scholar etc
- Sharing Option: Social Networking Enabled
- Authors, Reviewers and Editors rewarded with online Scientific Credits
- Better discount for your subsequent articles

Submit your manuscript at: <http://www.editorialmanager.com/medicalsciences/default.aspx>