

A Wire Located in the Heart - Case Report

Adam Stadnik, Kamil Baczewski* and Janusz Stążka

Department of Cardiac Surgery, Medical University of Lublin, Lublin, Poland

Abstract

Chest injury penetrating to the heart occurs relatively rarely. The additional presence of a foreign body in the right ventricle is even more uncommon. Thus, we aim to present the case report of a wire located in the heart of a 29-year-old woman. A decision to perform a surgery was based on patient's examination, chest X-ray, and computed tomography (CT). The patient was discharged from the hospital seven days after the surgery, symptom-free.

Keywords: Heart injury; Intracardiac foreign body; Penetrating chest injury; Accidentally heart injury

Introduction

Penetrating cardiac injury with isolated intracardiac foreign body located in the heart is a great challenge for a surgeon. In the case of our patient, we decided upon the open heart surgery with cardiopulmonary bypass (CPB) with very good results.

Case Report

A 29-year-old woman was admitted to the Emergency Room and diagnosed due to the non-specific chest pain located at the anterior chest wall near sternum, which started a few hours ago. During the physical examination, the woman complained of the shortness of breath and a small wound in the front of her chest. After questioning the patient, she admitted that she had been helping her husband with metal cutting at home. She did not have any comorbidities. The chest X-ray radiograph showed metallic densities within the cardiac silhouette. The doctors decided to perform computed tomography. This examination showed

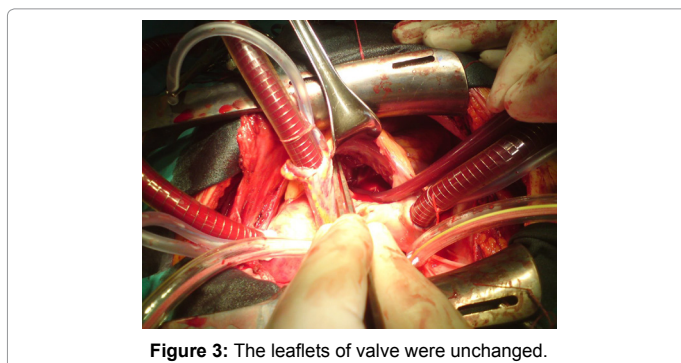


Figure 3: The leaflets of valve were unchanged.

that the metallic densities, which were not only inside the chest but also inside the right ventricle (Figures 1A-1D).

Based on complete examination, the Patient was transported to Cardiac Surgery Clinic and qualified to an urgent cardiac surgery. After the induction of anesthesia, the chest was opened, in the pericardial sac there was blood. Moreover, the surgeon noticed a small hole (1 mm) in the pericardial sac (Figure 2A). At first, the surgeon found the entry place of a foreign body in the right ventricle (Figure 2B). The team decided to cannulate the patient for a cardio-pulmonary bypass (CPB) without clamping the aorta. During the operation, the right atrium was opened and the metallic foreign body was removed from the right ventricle through the tricuspid valve, while the leaflets of valve were unchanged (Figure 3). Two stitches were put on the right ventricle in the place of injury. The time of CPB was 27 minutes.

In Intensive Care Unit, the condition of the patient was stable. Post-operative transthoracic echocardiography was normal. Valves had been working well without leaks; we did not find VSD or ASD. Post-operative course did not bring any complications and after 7-days treatment the patient left the hospital with a recommendation of a systematic medical control.

Discussion

This report presents a very rare case of a heart injury caused by the

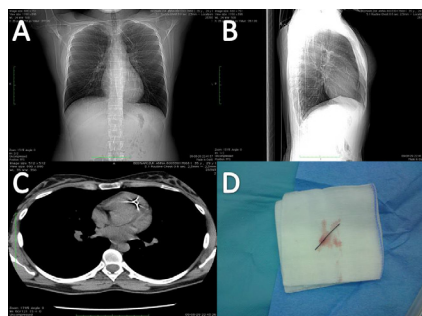


Figure 1: X-ray examination showing 35 metallic densities, which were not only inside the chest but also inside the right ventricle.

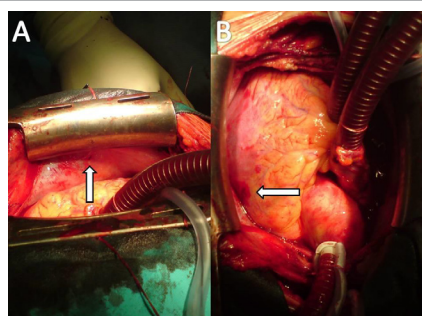


Figure 2: Figure showing blood in the chest and the pericardial sac after the induction of anesthesia. (A) A small hole of 1 mm found in the pericardial sac. (B) The entry place of a foreign body in the right ventricle.

*Corresponding author: Kamil Baczewski, Department of Cardiac Surgery, Medical University of Lublin, Hospital SPSK 4, Jaczewskiego 8, 20-954 Lublin, Poland, Tel: 0048817244940; Fax: 0048817244530; E-mail: drkamilbaczewski@gmail.com

Received March 02, 2017; Accepted April 10, 2017; Published April 17, 2017

Citation: Stadnik A, Baczewski K, Stążka J (2017) A Wire Located in the Heart - Case Report. J Clin Case Rep 7: 947. doi: [10.4172/2165-7920.1000947](https://doi.org/10.4172/2165-7920.1000947)

Copyright: © 2017 Stadnik A, et al. This is an open-access article distributed under the terms of the Creative Commons Attribution License, which permits unrestricted use, distribution, and reproduction in any medium, provided the original author and source are credited.

presence of a foreign body, namely the wire, inside the right ventricle. Early removal of the foreign body was recommended in order to prevent further damages to the heart. For the diagnosis, we used the chest X-ray and CT scan. Chest radiograph is usually the first imaging test performed on patients with cardiac injury. We performed a full sternotomy and an open heart surgery with CPB. In the case of any anterior cardiac involvement without suspicion of pulmonary injury, the chosen technique is the median sternotomy [1], as it allows for a better view of frontal injuries [2]. One case reports a removed foreign body inside the heart by means of the left mini-anterolateral thoracotomy without CPB [3].

The localization of a heart injury can be different but most frequently it involves the right ventricle as it was the case with our patient [1].

There was a reported case of a cardiac injury of a needle [4], sewing needle, bullets, missiles, a pencil or splinters. [4] Moreover, some heart injuries due to a screwdriver assault have been described [2], However accidentally chest or heart injury are very rare but we must keep it in mind [5].

Conclusion

We describe the right ventricular injury, without incision but with a small hole (1 mm) on the front wall of the chest. This case is extremely rare, yet extremely interesting. We have not found any other case report of a wire as a accidentally foreign body inside a patient's heart worldwide.

References

1. Beşir Y, Gökalp O, Eygi A, İner H, Peker I, et al. (2015) Choice of incision in penetrating cardiac injuries: Which one must we prefer: Thoracotomy or sternotomy?. *Ulus Travma Acil Cerrahi Derg* 4: 266-270.
2. Dieng PA, Diop MS, Ciss AG, Ba PS, Diatta S, et al. (2015) Penetrating heart injury due to screwdriver assault. *Case Rep Cardiol* p: 1-3.
3. Qian H, Song H, Li Y, Jiang C (2015) Removal of metallic foreign body in heart by minimally invasive procedure under the guidance of transesophageal echocardiography and transthoracic echocardiogram. *J Thorac Dis* 11: E560-E563.
4. Kim D, Yang PS, Choi JH, Seo J, Chun KH (2015) Metallic foreign body in heart mimicking moderator band. *Yonsei Med J* 56: 867-870.
5. Santavy P, Martin T, Vladimir L (2014) Metal splinter ejected by circular saw into the left ventricle. *Interact Cardiovasc Thorac Surg* 5: 881-882.

Citation: Stadnik A, Baczewski K, Stażka J (2017) A Wire Located in the Heart - Case Report. J Clin Case Rep 7: 947. doi: [10.4172/2165-7920.1000947](https://doi.org/10.4172/2165-7920.1000947)

OMICS International: Open Access Publication Benefits & Features

Unique features:

- Increased global visibility of articles through worldwide distribution and indexing
- Showcasing recent research output in a timely and updated manner
- Special issues on the current trends of scientific research

Special features:

- 700+ Open Access Journals
- 50,000+ editorial team
- Indexing at major indexing services
- Rapid review process
- Quality and quick editorial, review and publication processing
- Indexing at major indexing services
- Sharing Option: Social Networking Enabled
- Authors, Reviewers and Editors rewarded with online Scientific Credits
- Better discount for your subsequent articles

Submit your manuscript at: <http://www.omicsonline.org/submission//>