

Influence of Positive End-Expiratory Pressure Ventilation on Cerebral Perfusion and Cardiac Hemodynamics

Roland Backhaus¹, Elisabeth Torka¹, Michael Ertl^{2*}, Lukas Kirzinger¹, Andrea Wagner¹, Dobri Baldaranov¹, Felix Schlachetzki¹ and Kornelius Fuchs¹

¹Department of Neurology, University of Regensburg, Bezirksklinikum Regensburg, Germany

²Department of Neurology and Neurophysiology, Klinikum Augsburg Hospital, Augsburg, Germany

Abstract

Objective: Positive end-expiratory pressure (PEEP) ventilation is used to prevent alveolar collapse and improve oxygenation. PEEP ventilation hinders venous backflow to the right atrium as well as venous outflow from the brain including the spinal cord. This may have an effect on cardiac output (CO) and could result in an elevation in intracranial pressure (ICP) — an important cause of secondary brain injury. The aim of this study was to investigate the effect of moderate changes in PEEP values on hemodynamics and cerebral perfusion in neurological patients experiencing respiratory failure.

Methods: The study focused on 7 patients in a neurological intensive care unit who suffered from respiratory failure. Cerebral blood flow velocity was measured using transcranial color-coded duplex sonography (TCCS) while moderate changes in PEEP levels (10 cm, 7 cm or 5 cm H₂O) were made to investigate cerebral arterial blood flow velocity, third ventricular diameter, and midline shift. Simultaneously, cardiac output was measured using a minimally invasive hemodynamic monitoring system (Vigileo® or PiCCO®).

Results: Rising PEEPs resulted in a non-significant trend toward increased brain volume, as shown by a mild linear regression of changes in third ventricular diameter. However, no significant changes in cerebral blood flow parameters or hemodynamics values such as blood pressure, heart frequency or cardiac output, were noticed.

Conclusion: Low to moderate changes in PEEP appear to increase brain volume slightly, but cerebral autoregulatory compensatory mechanisms are sufficient to stabilize cerebral perfusion pressure and intravascular volume status. The effects of these changes in PEEP may be challenging in patients with impaired cerebral autoregulation (for example, in patients after subarachnoid hemorrhage or severe brain trauma) as well as in patients requiring a high level of PEEP ventilation (that is, patients with acute respiratory distress syndrome). In such patients TCCS and cardiac hemodynamics monitoring are warranted.

Keywords: Neurological intensive care; Positive end-expiratory pressure; Ventilation; Hemodynamics; Intracranial pressure; Non-invasive monitoring

Abbreviations: CO: Cardiac Output; CSF: Cerebrospinal Fluid; EDV: End-Diastolic Velocity; HR: Heart Rate; ICP: Intracranial Pressure; MAP: Mean Arterial Pressure; MCA: Middle Cerebral Artery; MLS: Midline Shift; PEEP: Positive End-Expiratory Pressure; PI: Pulsatility Index; PCO₂: Partial Pressure of Oxygen; PO₂: Partial Pressure of Oxygen; PP: Pulse Pressure; PSI: Peak Systolic Velocity; RI: Resistance Index; SD: Standard Deviation; SV: Stroke Volume; T_{avmax}: Time-Averaged Maximum Velocity; TCCS: Transcranial Color-Coded Duplex Sonography; TCD: Transcranial Doppler.

Introduction

Raised intracranial pressure (ICP) is a life-threatening state with a high risk of morbidity and mortality. ICP may be missed in sedated and artificially ventilated patients, in whom dilated pupils appear late when herniation is imminent. Invasive monitoring methods, such as ventricular drainage and microdialysis, are often used in neurosurgical patients with known or suspected raised ICP, but these methods carry inherent risks of their own. A reduction in cerebral perfusion pressure may lead to hypoxemia or stroke, further brain edema, and together with cerebral herniation to irreversible brain damage and poorer outcomes [1,2]. In intensive care medicine, noninvasive tools to measure ICP are often preferred but rarely available; resulting in a higher frequency in the use and reliance on cerebral computed tomography or magnetic resonance imaging.

Transcranial Doppler (TCD) sonography is a non-invasive, real-time bedside method used to measure cerebral blood flow and to determine resistance and pulsatility indices (RI and PI, respectively), which serve as indirect signs of raised ICP [3-5]. The complementary addition of B-mode sonography to TCD sonography, which results in transcranial color-coded duplex sonography (TCCS), allows for parenchymal assessments, specifically, measurements of ventricular width and midline displacement [6].

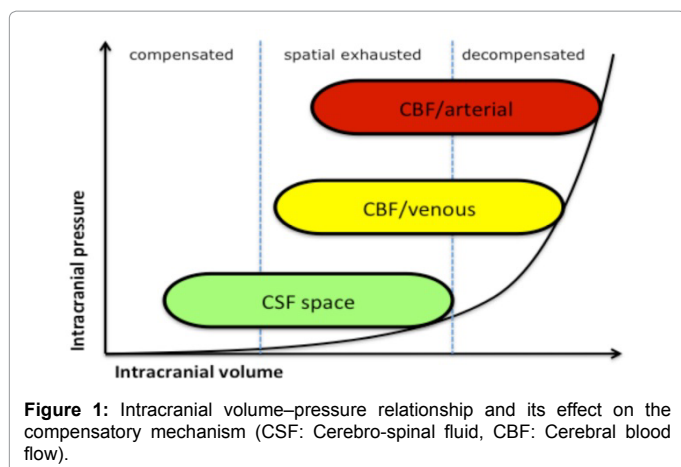
Following the Monro-Kellie doctrine, given a constant intracranial volume, compensation for intracranial hypertension can occur as long as the hypertension is in the low range [7,8]. The doctrine states that the sum of volumes of the three intracranial components of brain tissue, blood, and cerebrospinal fluid remains constant. A change in the volume of one component necessitates a modification of the volume of other components in a specific order to maintain a constant ICP. First, a caudal shift in intracranial CSF to the spinal compartment can

***Corresponding author:** Michael Ertl, Department of Neurology and Neurophysiology, Klinikum Augsburg Hospital, Augsburg, Germany, Tel: +49 821 400 2991; Fax: +49 821 400 2691; E-mail: Michael.Ertl@klinikum-augsburg.de

Received April 25, 2017; Accepted May 09, 2017; Published May 12, 2017

Citation: Backhaus R, Torka E, Ertl M, Kirzinger L, Wagner A, et al. (2017) Influence of Positive End-Expiratory Pressure Ventilation on Cerebral Perfusion and Cardiac Hemodynamics. J Depress Anxiety 6: 285. doi:10.4172/2167-1044.1000285

Copyright: © 2017 Backhaus R, et al. This is an open-access article distributed under the terms of the Creative Commons Attribution License, which permits unrestricted use, distribution, and reproduction in any medium, provided the original author and source are credited.



be observed. The effect of this CSF shift and change in volume may be monitored by measuring the diameter of the optic nerve sheath and the extent of papilledema by using transorbital ultrasonography [9-11]. Further increases in ICP reduce intracranial blood volume by compression of veins and sinuses, and eventually by compression of arterial vessels [12]. Once these mechanisms have been exhausted, ICP increases rapidly (Figure 1).

TCCS measurements are affected by several variables such as autoregulated diameters of pre-capillary arterioles as a reaction to changes in mean arterial pressure (MAP), proximal stenosis, vasospasm, or rising ICP. Physiologically, cerebral blood flow is mainly regulated by changes in the resistance of vessels at the level of pre-capillary arterioles. This is mostly subject to a metabolic autoregulatory mechanism that is not yet been completely understood [13]. However, in the context of pathological processes of the brain, this auto regulation is often disturbed and becomes a sign of poor prognosis.

In this study we investigated whether increasing positive end-expiratory pressure (PEEP) has an effect on brain volume and, consequently, ICP as well as on CO. The results of previous studies on the influence of PEEP on ICP have been controversial [14-16].

The aim of this prospective study was to evaluate the influence of moderate changes in PEEP on hemodynamics and indirect signs of ICP depicted on TCCS images.

Methods

Patients

The study group consisted of 7 patients who had been admitted to the Neurological Intensive Care Unit at the University of Regensburg Bezirksklinikum. The study was approved by the local ethics committee of the University Clinic Regensburg in accordance with guidelines of the Declaration of Helsinki (Ethic votum No: 10-101-0235).

Inclusion criteria

Enrolled were patients at least 18 years of age, who were provided with analgesia and sedation, given mechanical ventilation, and in a stable condition without any expected elevation in ICP. Informed consent was obtained from all participating patients. The patients underwent examination while in the 45° head-up position, and ventilation was provided using a pressure-controlled, pressure-regulated mode. The same ventilator type (Centiva Elisa, Salvia Liftec, Germany) was used for all patients.

Neurosonology examination was performed three times at different PEEP parameters (10 cm, 7 cm and 5 cm H₂O). The PEEP was stable for at least 5 minutes before the examination was completed. We measured each patient's cerebral perfusion, pulsatility index ($PI = (PSV - EDV) / TAV_{max}$), and resistance index ($RI = (PSV - EDV) / TAV_{max}$), which serve as indirect signs of intracranial compliance and pressure [17-19]. In each patient, the right and left middle cerebral arteries (MCAs) were identified at an insonation of 52–58 mm. During B-mode imaging, the diameter of the third ventricle was measured from both sides. A midline shift (MLS) was calculated by measuring the distance from the transducer to the center of the third ventricle on both left (distance A) and right (distance B) sides, and then dividing the resulting number in half ($MLS = (A - B) / 2$) [20]. The examination was performed at the patient's bedside using a CX50 system (Philips, Bothell, WA, USA) for transcranial imaging and a CV70 unit (Siemens, Erlangen, Germany) for extracranial sonography. A sector transducer with a transmission frequency of 2 MHz was used for TCCS on both sides through a temporal bone window using 5–7 MHz for extracranial imaging. All images were manually optimized for brightness, color, and Doppler mode; and these settings were kept constant for each patient. Images were stored as DICOM files in the ultrasound archive system (Clinic Win Data, Erlangen, Germany) for offline analysis.

Ultrasound contrast agent (SonoVue, Bracco, Italy) was applied in one case because an examination through the temporal bone window was insufficient. (Known intolerance to the contrast agent was an exclusion criterion.) The contrast agent was later used in all follow-up examinations in this case.

At each session we monitored the patient's CO, systolic blood pressure, MAP, and central venous pressure using the minimally invasive Vigileo-System. CO depends on stroke volume (SV) and heart rate (HR): ($CO = HR \times SV$). Cardiac output could be measured using the classic temperature dilution method with the Stewart-Hamilton equation. To simplify this method algorithms are used to describe CO in a minimally invasive manner by using pulse pressure (PP) multiplicity with a factor that integrates age, sex, body weight, height and vessel compliance among others (Vigileo-System, Edwards/Life Sciences) [21,22]. Another algorithm used to define the CO in a minimally invasive fashion correlates the arterial pulse contour with CO measured using the temperature dilution method (PiCCO-System, Pulsion) [23]. Both methods have been sufficiently validated for clinical use.

Also registered was the patient's inspiratory oxygen concentration as well as the inspiration/expiration ratio. In blood gas analyses, metabolic parameters were measured along with pCO₂ and pO₂.

Statistical Analysis

The study was performed using a prospective design. Excel (Windows version) was used for collection and analysis of data. Summary statistics are shown in this paper as mean values with standard deviations (SDs) as well as ranges of continuous parameters. Pictorial presentation of some results are provided in bar and line graphs; other data are displayed in tables.

Results

Transcranial duplex ultrasound

The mean diameter of the third ventricle, which was insonated from both sides, was 5.67 mm (SD 2.74) at a PEEP of 10 cm H₂O, 5.79 mm (SD 2.84) at a PEEP of 7 cm H₂O, and 5.84 mm (SD 3.02) at a PEEP of 5 cm H₂O. These values displayed a negative linear correlation

| Diameter of the Third Ventricle (mm) | | | | | | | | | |
|--------------------------------------|-----|-----|---------------------|----------------------------|----------------------------|-----------------------------|--------------------------------|------|-------|
| Case | Sex | Age | Diagnosis | PEEP 5 cm H ₂ O | PEEP 7 cm H ₂ O | PEEP 10 cm H ₂ O | delta 5–10 cm H ₂ O | Mean | SD |
| 1 | F | 57 | Status Epilepticus | 4.98 | 4.88 | 5 | 0.02 | 4.95 | 0.052 |
| 2 | F | 74 | Status Epilepticus | 6.29 | 6.16 | 6 | -0.71 | 6.15 | 0.119 |
| 3 | F | 81 | Stroke | 5.72 | 5.58 | 5.6 | -0.12 | 5.63 | 0.062 |
| 4 | M | 67 | Stroke | 9.42 | 8.49 | 8.48 | -0.94 | 8.8 | 0.441 |
| 5 | M | 54 | Leukoencephalopathy | 2 | 2.15 | 2.64 | 0.64 | 2.26 | 0.273 |
| 6 | M | 81 | Status Epilepticus | 11.3 | 11.45 | 10.66 | -0.64 | 7.8 | 0.343 |
| 7 | M | 76 | Status Epilepticus | 3.35 | 2.65 | 2.5 | -0.85 | 2.83 | 0.371 |

Table 1: Comparison of third ventricle diameters at different PEEP levels.

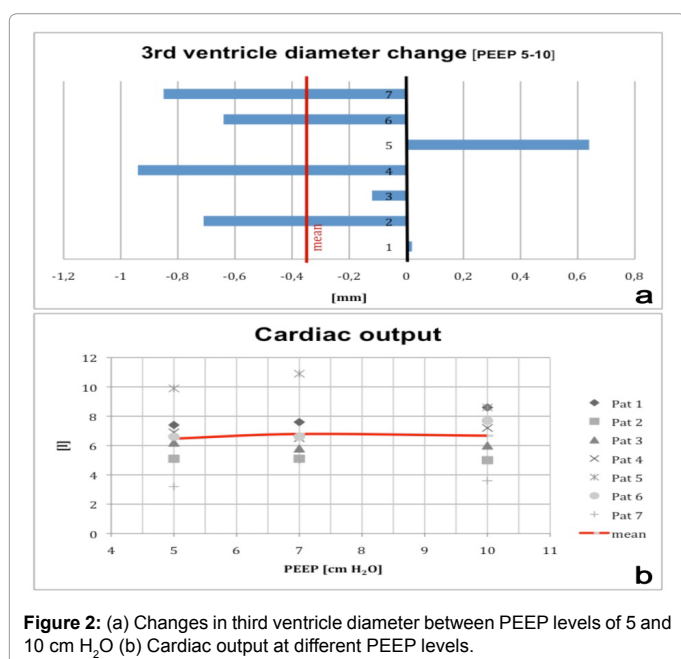


Figure 2: (a) Changes in third ventricle diameter between PEEP levels of 5 and 10 cm H₂O (b) Cardiac output at different PEEP levels.

| Cardiac Output (L/min) | | | | | | |
|------------------------|----------------------------|----------------------------|-----------------------------|--------------------------------|------|-------|
| Case | PEEP 5 cm H ₂ O | PEEP 7 cm H ₂ O | PEEP 10 cm H ₂ O | delta 5–10 cm H ₂ O | Mean | SD |
| 1 | 7.4 | 7.6 | 8.6 | 1.2 | 7.9 | 0.643 |
| 2 | 5.1 | 5.1 | 5 | -0.1 | 5.1 | 0.057 |
| 3 | 6.2 | 5.8 | 6 | -0.2 | 4.5 | 0.200 |
| 4 | 6.9 | 6.5 | 7.2 | 0.3 | 6.9 | 0.352 |
| 5 | 9.9 | 10.9 | 8.6 | -1.3 | 9.8 | 1.153 |
| 6 | 6.6 | 6.6 | 7.7 | 1.1 | 7 | 0.635 |
| 7 | 3.2 | 5 | 3.6 | 0.4 | 3.9 | 0.945 |

Table 2: Comparison of cardiac output at different PEEP levels.

between a rising PEEP and the diameter of third ventricle, but without statistical significance ($p = 0.81$).

The midline, which was insonated from both left and right sides, was detected at a median depth of 75–79 mm. A change in PEEP did not demonstrate a relevant deviation in the midline correlation to PEEP changes ($p = 0.5$).

The mean blood flow velocity at a PEEP of 10 cm H₂O in the left MCA was 52.0 cm/s. A reduction in PEEP to 7 cm H₂O showed a non-significant relative decrease in mean blood flow velocity to 49.0 cm/s. At a PEEP of 5 cm H₂O, the mean blood flow velocity was 52.7 cm/s, which also was not statistically relevant. There were no statistically relevant changes for the right MCA either.

The mean PI of the left MCA was 1.12 at a PEEP of 10 cm H₂O, 1.14

at a PEEP of 7 cm H₂O, and 1.5 at a PEEP of 5 cm H₂O ($p = 0.47$ for a comparison between PEEPs of 10 and 5 cm H₂O). The RI of the left MCA was 0.64 at a PEEP of 10 cm H₂O, 0.65 at a PEEP of 7 cm H₂O, and 0.67 at a PEEP of 5 cm H₂O ($p = 0.47$ for a comparison between PEEPs of 10 and 5 cm H₂O). No significant changes were found for the right MCA either.

Overall, blood flow velocity, PI, and RI did not change significantly at different PEEP levels (Table 1 and Figure 2a).

Hemodynamics

The mean cardiac output was 6.47 L/min at a PEEP of 5 cm H₂O, 6.79 L/min at a PEEP of 7 cm H₂O, and 6.67 L/min at a PEEP of 10 cm H₂O ($p = 0.58$ for a comparison between PEEPs of 10 and 5 cm H₂O). No effect of changes in PEEP on heart rate could be observed. Values of systolic and diastolic blood pressures (BPs) remained constant. Systolic BPs ranged from 153 to 157 mmHg and diastolic BPs ranged from 73 to 76 mmHg.

The mean peripheral resistance [$\text{dyn} \cdot \text{sec} \cdot \text{cm}^{-5}$] was 1571 at a PEEP of 5 cm H₂O, 1637 at a PEEP of 7 cm H₂O, and 1386 at a PEEP of 10 cm H₂O; there was no statistical relevance ($p = 0.44$ for a comparison between PEEPs of 10 and 5 cm H₂O).

None of the measurements that we obtained demonstrated any significant changes at the moderate PEEP levels used in this study. This may be due to preserved cerebral auto regulation capacity, low ICP in the examined patients, and appropriate volume therapy—an essential requirement for sufficient hemodynamics and thus sufficient oxygenation of the tissue (Table 2 and Figure 2b).

Discussion

In this pilot study, we investigated the influence of low to moderate changes in PEEP on intracranial perfusion, as indirect signs of rising ICP, as well as on cardiovascular hemodynamics. Overall, our data demonstrated no significant effects, although we did identify a negative correlation between elevations in PEEP and decreasing diameters of the third ventricle; this confirms a mild effect on brain volume from decreased venous outflow. These results confirm the safety of mild PEEP changes for both brain and cardiac output in primarily neurological patients, suggesting an intact cerebral auto regulation and a sufficient volume status in this small patient population.

Auto regulation, ICP, and neurovascular coupling

Cerebral blood flow and auto regulation are influenced by systemic cardiopulmonary variables, cerebrovascular reactivity, and neurovascular coupling; and they can be impaired by a brain injury such as ischemia, trauma, septic encephalopathy or tumor [24,25]. The impact of cerebral injury and consequent disturbed cerebral auto regulation may have a strong influence on outcome.

Auto regulation of ICP is an important mechanism in the prevention of secondary damage to the brain [26]. The effect of blood-brain barrier disruption is known; particularly in cases of cerebral ischemia, it results in a neuro inflammatory response that is attended by edema and has consequences for ICP and vascular auto regulation [27]. Cooper et al. [28] examined 33 patients with severe head injury to determine whether changes in PEEP would cause an increase in ICP. Other physiological variables, such as cardiac output and cerebral perfusion (determined by ultrasonography), were also measured. The authors concluded that 10 cm H₂O PEEP increases ICP slightly through an effect on other physiological variables, but found no clinical consequence [28]. Another prospective study undertaken by Caricato et al. [29] involved examination of 21 patients with head injury and subarachnoid hemorrhage who were given mechanical ventilation. In accordance with the study design, these patients were compared with one group of patients with normal respiratory system compliance and another group of patients with low respiratory system compliance. In the latter two groups PEEP was raised from 0 to 12 cm H₂O in defined sequences. Overall, in patients with low respiratory system compliance, transcranial ultrasound studies found no significant effect of PEEP elevation on cerebral or systemic hemodynamics [29]. In patients with acute respiratory distress syndrome, but no neurological disease, who were examined by Schramm and colleagues [16] using TCD sonography, higher levels of PEEP (9.2–14.3 cm H₂O) had no influence on cerebral blood flow, but there were signs of impaired autoregulation in 55% of patients. Videtta et al. [30] found no significant increase in ICP (using a parenchymal sensor) when they elevated the PEEP from 5 to 15 cm H₂O in 20 patients. In that study the patients suffered from severe head injury or from some type of intracranial haemorrhage. PEEP was raised from 5 to 15 cm H₂O for 10 minutes before ICP and cerebral perfusion were measured. The elevation in PEEP resulted in a significant increase in ICP ($p < 0.05$) with no changes in cerebral perfusion. Georgiadis et al. [31] evaluated 20 patients with acute stroke and examined the effects of changes in PEEP between 4 and 12 cm H₂O on ICP (measured using a parenchymal ICP sensor), heart rate, MAP (determined using radial artery cannulation) and the mean velocity of the MCAs (measured using TCCS). The authors concluded that there was a negligible effect of PEEP on ICP. They also stated that changes in cerebral perfusion pressure are mediated through changes in MAP and indirectly through increases in ICP caused by cerebral vasodilation in patients with intact cerebral autoregulation.

Hemodynamics

With respect to the aforementioned cardiopulmonary effects of PEEP, the primary finding was that a modification in vascular lung compartment results in a change in intra thoracic pressure. Cardiac effects differ between the right and left ventricles and can be grouped into three types: ventricular preload, afterload, and contractility [32].

Ventricular preload depends on systemic venous return, ventricular output, and ventricular filling [33]. In the left ventricle PEEP reduces preload and afterload while preserving contractility. In the right ventricle a lower PEEP (< 10 mmHg) reduces the preload without influencing contractility, whereas a higher PEEP (> 10 mmHg) causes decreases in both preload and afterload. A broad intravascular volume can reduce these effects. Factors like sufficient volume status seem to play a much larger role in optimal cerebral perfusion.

Usually, a change in heart rate cannot be observed, as our data support. Viquerat et al. found a decrease in cardiac output by increasing PEEP to 12 cm H₂O but concluded that a reduction in preload might be the primary cause [34]. In 50 children who received mechanical

ventilation and were hemodynamically stable, Ingaramo and colleagues found no difference in heart rate or blood pressure when PEEP was raised from 0 to 12 cm H₂O [35]. However, higher PEEP levels might have an exponential effect on ICP.

The influence of PEEP on both intracranial and cardiac hemodynamics may increase when there is severe brain injury with damaged cerebral auto regulation. In Case 5 in the present study, we observed unusual effects of PEEP changes. This patient suffered from acute and complete leuko encephalopathy of the brain—the histopathological report determined almost exclusively demyelination process—with an unknown trigger, resulting in a breakdown of neurovascular coupling. In high-risk patients, such as intubated and ventilated patients in a neurological intensive care unit, it is of critical importance that sufficient cerebral perfusion be monitored. Factors like sufficient volume status seem to play a much larger role in optimal cerebral perfusion. Given the Monro-Kellie doctrine, according to which ICP can remain constant by modifications in brain component's volume, exhaustion of the compensatory mechanism might have an exponential effect on ICP, even in the presence of low elevations in PEEP if ICP is at a critical level.

Limitations of the study

The current study has several limitations. There were very few patients. The study protocol does not include known vascular risk factors such as pre-existing arteriosclerosis or vasculitis, heart failure, or pulmonary diseases with suspected hemodynamic relevance or resistance of vessels. Other factors not taken into account are medications such as beta-blockers or catecholamine, which produce intentional vascular or hemodynamic effects.

Conclusion

Low to moderate changes in PEEP in patients who receive mechanical ventilation for neurological injury or disease is safe and has no significant impact on cerebral perfusion and hemodynamics, despite a tendency toward increased intracranial volume, which could be observed by decreases in the diameter of the third ventricle.

TCCS in combination with non-invasive hemodynamics monitoring of the cardiac output is an easily available method for bedside evaluation of cerebral auto regulation and ICP; it allows steady state investigation without the risk attending transportation to diagnostics. The data we obtained in this study suggest that with respect to intra thoracic pressure and, therefore reduced cardiac preload, the influence of cerebral auto regulation is superior to that of PEEP. Further studies taking into account various cerebral diseases and changes in ICP at different PEEP levels should be undertaken in a larger population of patients.

Acknowledgment

The authors thank all participating physicians for their effort and support. A special acknowledgement for support in statistics is Professor Wilhelm Schulte-Mattler. The authors also thank Jo Ann M. Eliason, MA, ELS(D), for English editing assistance.

References

1. Le Roux P (2014) Intracranial pressure after the BEST TRIP trial: A call for more monitoring. *Curr Opin Crit Care* 20: 141-147.
2. Dias C, Silva MJ, Pereira E, Monteiro E, Maia I, et al. (2015) Optimal cerebral perfusion pressure management at bedside: A single-center pilot study. *Neurocrit Care* 23: 92-102.
3. Kipthuth IC, Huttner HB, Dörfler A, Schwab S, Köhrmann M (2013) Doppler pulsatility index in spontaneous intracerebral hemorrhage. *Eur Neurol* 70(3-4): 133-138.

4. Kalanuria A, Nyquist PA, Armonda RA, Razumovsky A (2013) Use of Transcranial Doppler (TCD) ultrasound in the neurocritical care unit. *Neurosurg Clin N Am* 24: 441-456.
5. Rasulo FA, De Peri E, Lavinio A (2008) Transcranial doppler ultrasonography in intensive care. *Eur J Anaesthesiol Suppl* 42: 167-173.
6. Motuel J, Biette I, Srairi M, Mrozek S, Kurrek MM, et al. (2014) Assessment of brain midline shift using sonography in neurosurgical ICU patients. *Crit Care* 18: 676.
7. Schaller B, Graf R (2005) Different compartments of intracranial pressure and its relationship to cerebral blood flow. *J Trauma* 59: 1521-1531.
8. Mokri B (2001) The Monro-Kellie hypothesis: Applications in CSF volume depletion. *Neurology* 26: 1746-1748.
9. Ertl M, Barinka F, Torka E, Altmann M, Pfister K, et al. (2014) Ocular color-coded sonography - A promising tool for neurologists and intensive care physicians. *Ultra Schall Med* 35: 422-431.
10. Tamburrelli C, Salgarello T, Caputo CG, Giudiceandrea A, Scullica L (2000) Ultrasonographic evaluation of optic disc swelling: Comparison with CSLO in idiopathic intracranial hypertension. *Invest Ophthalmol Vis Sci* 41(10): 2960-2966.
11. Bäuerle J, Nedelmann M (2011) Sonographic assessment of the optic nerve sheath in idiopathic intracranial hypertension. *J Neurol* 258: 2014-2019.
12. Wang Y, Duan YY, Zhou HY, Yuan LJ, Zhang L, et al. (2014) Middle cerebral arterial flow changes on transcranial color and spectral Doppler sonography in patients with increased intracranial pressure. *J Ultrasound Med* 33: 2131-2136.
13. Paulson OB, Strandgaard S, Edvinsson L (1990) Cerebral autoregulation. *Cerebrovasc Brain Metab Rev* 2: 161-192.
14. Jauncey-Cooke JI, Bogossian F, East CE (2009) Lung recruitment - A guide for clinicians. *Aust Crit Care* 22: 155-162.
15. Fares WH, Carson SS (2013) The relationship between positive end-expiratory pressure and cardiac index in patients with acute respiratory distress syndrome. *J Crit Care* 28: 992-997.
16. Schramm P, Closhen D, Felkel M, Berres M, Klein KU, et al. (2013) Influence of PEEP on cerebral blood flow and cerebrovascular autoregulation in patients with acute respiratory distress syndrome. *J Neurosurg Anesthesiol* 25: 162-167.
17. Beasley MG, Blau JN, Gosling RG (1979) Changes in internal carotid artery flow velocities with cerebral vasodilation and constriction. *Stroke* 10: 172-179.
18. Arbeille P, Roncin A, Berson M, Patat F, Pourcelot L (1987) Exploration of the fetal cerebral blood flow by duplex Doppler-linear array system in normal and pathological pregnancies. *Ultrasound Med Biol* 13: 329-337.
19. Valdeuza ua, *Neurosonology and Neuroimaging of Stroke* © 2008 Georg Thieme Verlag KG Stuttgart New York ISBN 9783131418715
20. Gerriets T, Stolz E, Modrau B, Fiss I, Seidel G, et al. (1999) Sonographic monitoring of midline shift in hemispheric infarctions. *Neurology* 52: 45-49.
21. Breukers RM, Seppehrkhoy S, Spiegelenberg SR, Groeneveld AB (2007) Cardiac output measured by a new arterial pressure waveform analysis method without calibration compared with thermo-dilution after cardiac surgery. *J Cardiothorac Vasc Anesth* 21: 632-635.
22. Guarracino F, Stefani M, Lapolla F, Cariello C, Doroni L, et al. (2007) Monitoring cardiac output with Flo Trac Vigileo. *Br J Anaesth* 99: 142.
23. Cottis R, Magee N, Higgins DJ (2003) Haemodynamic monitoring with pulse-induced contour cardiac output (PiCCO) in critical care. *Intensive Crit Care Nurs* 19: 301-307.
24. Salinet AS, Robinson TG, Panerai RB (1985) Effects of cerebral ischemia on human neurovascular coupling, CO₂ reactivity, and dynamic cerebral autoregulation. *J Appl Physiol* 15;118: 170-177.
25. Paulson OB (2008) Heart and brain circulation in healthy men are differently affected by CO₂. *Acta Physiol (Oxf)* 193: 203.
26. Czosnyka M, Miller C (2014) Monitoring of cerebral autoregulation. *Neurocrit Care* 2: 95-102.
27. Yang Y, Rosenberg GA (2011) Blood-brain barrier breakdown in acute and chronic cerebrovascular disease. *Stroke* 42: 3323-3328.
28. Cooper KR, Boswell PA, Choi SC (1985) Safe use of PEEP in patients with severe head injury. *J Neurosurg* 63: 552-555.
29. Caricato A, Conti G, Della Corte F, Mancino A, Santilli F, et al. (2005) Effects of PEEP on the intracranial system of patients with head injury and subarachnoid hemorrhage: The role of respiratory system compliance. *J Trauma* 58: 571-576.
30. Videtta W, Villarejo F, Cohen M, Domeniconi G, Santa Cruz R, et al. (2002) Effects of positive end-expiratory pressure on intracranial pressure and cerebral perfusion pressure. *Acta Neurochir Suppl.* 81: 93-97.
31. Georgiadis D, Schwarz S, Baumgartner RW, Veltkamp R, Schwab S (2001) Influence of positive end-expiratory pressure on intracranial pressure and cerebral perfusion pressure in patients with acute stroke. *Stroke* 32: 2088-2092.
32. Pinsky MR (1997) The hemodynamic consequences of mechanical ventilation: an evolving story. *Intensive Care Med* 23: 493-503.
33. Luecke T, Pelosi P (2005) Clinical review: Positive end-expiratory pressure and cardiac output. *Crit Care* 9: 607-621.
34. Viquerat CE, Righetti A, Suter PM (1983) Biventricular volumes and function in patients with adult respiratory distress syndrome ventilated with PEEP. *Chest* 83: 509-514.
35. Ingaramo OA, Ngo T, Khemani RG, Newth CJ (2014) Impact of positive end-expiratory pressure on cardiac index measured by ultrasound cardiac output monitor. *Pediatr Crit Care Med* 15: 15-20.

Citation: Backhaus R, Torka E, Ertl M, Kirzinger L, Wagner A, et al. (2017) Influence of Positive End-Expiratory Pressure Ventilation on Cerebral Perfusion and Cardiac Hemodynamics. *J Depress Anxiety* 6: 285. doi:[10.4172/2167-1044.1000285](https://doi.org/10.4172/2167-1044.1000285)

OMICS International: Open Access Publication Benefits & Features

Unique features:

- Increased global visibility of articles through worldwide distribution and indexing
- Showcasing recent research output in a timely and updated manner
- Special issues on the current trends of scientific research

Special features:

- 700+ Open Access Journals
- 50,000+ Editorial team
- Rapid review process
- Quality and quick editorial, review and publication processing
- Indexing at major indexing services
- Sharing Option: Social Networking Enabled
- Authors, Reviewers and Editors rewarded with online Scientific Credits
- Better discount for your subsequent articles

Submit your manuscript at: <http://www.omicsonline.org/submit>