

Placenta Increta at Unscarred Area in a Previous Caesarean Women: A Case Report of an Unusual Pathogenesis of Usual Etiology

Supriya Dankher*, Sumitra Bachani, Preeti Bala Patel and Swati Shivhare

Department of Obstetrics and Gynaecology, VMMC and Safdarjung Hospital, India

Abstract

Morbidly adherent placenta usually presents with heavy bleeding and difficulty in placental removal in the third stage. Although association of morbidly adherent placenta with previous caesarean section or uterine surgery is well documented the exact pathogenesis of placenta accrete still remains unknown. We hereby report a case of spontaneous second trimester abortion followed by recurrent intermittent hemorrhage leading to hypovolemic shock. Following this hysterectomy was done, which on histopathology revealed placenta increta away from previous uterine scar site. Pathogenesis in this case for morbidly adherent placentation seems to be resembling that in a woman without any previous uterine surgery or scar, which is quite unusual. We report this case with a brief review of the literature.

Keywords: Morbidly adherent placenta; Placenta accreta; Hysterectomy, Postabortal haemorrhage; Previous caesarean section

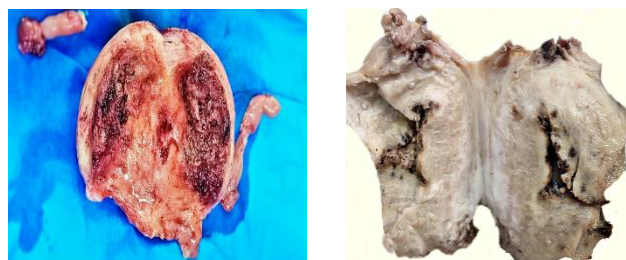Introduction

Postabortal hemorrhage is clinically defined as amount of blood loss in excess of 500 mL requiring hospital admission and/or transfusion. The causes of postabortal hemorrhage in order of frequency were uterine atony, abnormal placentation, cervical laceration, perforation and disseminated intravascular coagulopathy [1]. Abnormal placentation includes morbidly adherent placenta and exaggerated placental site activity. Morbidly adherent placenta is characterized by complete or partial absence of the decidua basalis and imperfect development of the fibrinoid layer (Nitabuch layer) leading to chorionic villi to invade the myometrium abnormally. Adherent placenta accounts for 7% to 10% of maternal mortality worldwide [2]. It is divided into three grades based on histopathology: placenta accreta where the chorionic villi are in contact with the myometrium, placenta increta where the chorionic villi invade the myometrium, and placenta percreta where the chorionic villi penetrate the uterine serosa. Several risk factors for placenta accreta have been reported, including a previous cesarean delivery particularly when accompanied with a coexisting placenta previa, previous uterine surgery like myomectomy and uterine curettage, maternal age over 35 years and smoking [3]. We hereby present an unusual case of spontaneous second trimester abortion followed by recurrent intermittent hemorrhage leading to hypovolemic shock.

Case Report

A 27-year-old P2L2A1 with previous 2 LSCS presented to our emergency department on post abortal day 14 with chief complaints of excessive bleeding per vaginum on and off for last 10 days. She had a spontaneous abortion at four months of gestation followed by dilation and evacuation in v/o incomplete abortion 14 days back. On examination, her vitals were stable, pallor was present and abdomen was soft with no guarding, tenderness or rigidity. On per vaginum examination internal os was open, uterus was enlarged to 10 weeks size with products of conception felt inside the cavity and fornices were free. Patient was shifted to OT for evacuation under anaesthesia in v/o incomplete abortion, with previous LSCS, anaemia and history of surgical evacuation already being attempted, considering the possibility of morbidly adherent placenta. Surgical evacuation was done in OT and tissue obtained was suggestive of POC which was sent for HPE. There no active bleeding per vaginum after evacuation. She received adequate blood products as per her haemoglobin and was stable after the

procedure. She had a bout of bleeding six hours after evacuation with a blood loss of around 100 mL. An emergency sonography was done in the radiology department in order to rule out RPOCs or placenta accrete. It revealed an ill-defined hypoechoic area 4.4 cm × 2.2 cm s/o clot in view of no internal vascularity but was advised MRI for further confirmation which was scheduled for next day. However, she had another bout of bleeding with loss of around 800 mL blood on the same day leading to compensated hypovolemic shock. Hence patient was taken up for emergency subtotal hysterectomy. Uterus with bilateral fallopian tubes were removed and sent for HPE. On cut section, a rough area seen with some adhered bits of placental tissue an anterior wall of uterine body (Figures 1 and 2). On histopathological examination, it was reported to be a focal placenta increta, chorionic villi invading myometrium were seen in upper part of anterior surface of body of uterus (Figure 3). Bilateral fallopian tubes were unremarkable. Histopathology of tissue obtained after evacuation was also reported as normal products of conception. Postoperative period was uneventful and patient was discharged after suture removal.



Figures 1 and 2: Cut section of subtotal hysterectomy specimen showing upper segment placenta increta.

*Corresponding author: Supriya Dankher, Department of Obstetrics and Gynaecology, VMMC and Safdarjung Hospital, India, Tel: 91- 8505813686; E-mail: supsdthankher@gmail.com

Received May 10, 2017; Accepted June 20, 2017; Published June 25, 2017

Citation: Dankher S, Bachani S, Patel PB, Shivhare S (2017) Placenta Increta at Unscarred Area in a Previous Caesarean Women: A Case Report of an Unusual Pathogenesis of Usual Etiology. J Clin Case Rep 7: 983. doi: [10.4172/2165-7920.1000983](https://doi.org/10.4172/2165-7920.1000983)

Copyright: © 2017 Dankher S, et al. This is an open-access article distributed under the terms of the Creative Commons Attribution License, which permits unrestricted use, distribution, and reproduction in any medium, provided the original author and source are credited.

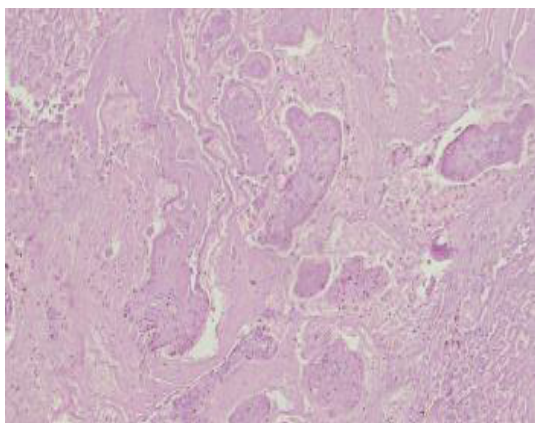


Figure 3: Histopathological examination showing placenta increta.

Discussion

Morbidly adherent placenta is not a rare association in women with previous caesarean section. It usually presents with vaginal bleeding during difficult placental removal in the third-trimester. Unlike this, in our case it presented as intermittent bleeding following a second trimester abortion. A case of placenta increta diagnosed after emergency hysterectomy done in view of intraperitoneal bleeding two months after an uncomplicated dilatation and curettage for first trimester abortion was also reported [4]. Also, Choi et al. reported uterine rupture in normal intrauterine pregnancy at 13 weeks of gestation due to placenta percreta [5]. Pathogenesis of morbidly adherent placenta in cases of women with previous caesarean section is believed as defective decidualization, abnormal maternal vascular remodeling, excessive trophoblastic invasion or combinations as implantation occurs at uterine scar site. Increasing numbers of prior cesarean deliveries exponentially increase the risk of placenta accrete [6-11]. In the present case placenta was upper segment much away from the scar of previous two lower segment caesarean sections and there was no history of any other uterine surgery or instrumentation. All these points are not in favour of placenta accreta, hence pathogenesis for placenta accreta in this case was similar to women without any previous uterine surgery or instrumentation. Cohen et al. reported that the cytotrophoblast secretes factors that favour invasion, whereas decidua does not seem to have a major role in regulating cytotrophoblast invasion *in vitro* [12]. On the contrary Earl et al. reported that it is unlikely that overactive trophoblastic invasion plays a major role in the pathogenesis of placenta accreta, and the absence of decidua is of greater importance in the pathogenesis [13]. Placenta percreta was also reported in primigravida with no known significant risk factors and diagnosis was established at the time of caesarean delivery [2]. Garmi et al. demonstrated *in vitro* that an induced sharp decidual incision, imitating the *in vivo* process that is caesarean section increased the invasive potential of the trophoblastic

cells [3]. Additionally, complete re approximation of the incised edges of the decidua *in vitro* made the incised decidua to behave similarly to intact decidua while restricting once again the extent of the invasiveness. Using the same cohort of trophoblast cells, while changing only the decidual anatomic characteristics the invasive potential of trophoblastic cells *in vitro* changed accordingly emphasizing the role of decidua on the invasive potential [3].

Conclusion

Present case suggests that in women at risk for invasive placentation who present with abnormal uterine bleeding following recent spontaneous or therapeutic abortion, morbidly adherent placenta should be considered among the differential diagnosis. Also, placenta accreta when focal and at the previous scar site only implicates previous uterine scar as its etiology but if not so, pathogenesis is similar to one in unscarred uterus. In conclusion, as recently there is a rapid rise in incidence of morbidly adherent placenta and this is always viewed in context of rising incidence of caesarean section, cases like ours emphasizes on importance of further research in pathogenesis of this serious condition.

References

1. Kerns J, Steinauer J (2013) Management of postabortion hemorrhage. *Contraception* 87: 331-342.
2. Rajkumar B, Kumar N, Sirinivasan S (2014) Placenta percreta in primigravida, an unsuspected situation. *Int J Reprod Contracept Obstet Gynecol* 3: 239-241.
3. Garmi G, Salim R (2012) Epidemiology, etiology, diagnosis, and management of placenta accreta. *Obstet Gynecol Int J* 1-7.
4. Son G, Kwon J, Cho H, Kim S (2007) *J Korean Med Sci* 22: 932-935.
5. Choi GD, Choi WK, Lee HS, Kim CB, Lee GN (1996) A case of spontaneous rupture of the uterus with placenta increta in early pregnancy. *Korean J Obstet Gynecol* 39: 1359.
6. Wu M, Kocherginsky J, Hibbard U (2005) Abnormal placentation: Twenty-year analysis. *Am J Obstet Gynecol* 192: 1458-1461.
7. DA Miller, JA Chollet, TM Goodwin (1997) Clinical risk factors for placenta previaplacenta accreta. *Am J Obstet Gynecol* 177: 210-214.
8. SL Clark, PP Koonings, JP Phelan (1985) Placenta previa/accreta and prior caesarean section. *Obstet Gynecol* 66: 89-92.
9. Gielchinsky Y, Rojansky N, Fasouliotis SJ, Ezra Y (2002) Placenta accrete-summary of 10 years: A survey of 310 cases. *Placenta* 23: 210-214.
10. Sivan E, Spira M, Achiron R (2010) Prophylactic pelvic artery catheterization and embolization in women with placenta accreta: Can it prevent caesarean hysterectomy? *Am J Perinat* 27: 455-461.
11. Tantbirojn P, Crum CP, Parast MM (2008) Pathophysiology of placenta accreta: The role of decidua and extravillous trophoblast. *Placenta* 29: 639-645.
12. Cohen M, Wuillemin C, Irion O, Bischof P (2010) Role of decidua in trophoblastic invasion. *Neuroendocrinol Lett* 31: 193-197.
13. Earl U, Bulmer JN, Briones A (1987) Placenta accreta: An immunohistological study of trophoblast populations. *Placenta* 8: 273-282.

Citation: Dankher S, Bachani S, Patel PB, Shivhare S (2017) Placenta Increta at Unscarred Area in a Previous Caesarean Women: A Case Report of an Unusual Pathogenesis of Usual Etiology. J Clin Case Rep 7: 983. doi: [10.4172/2165-7920.1000983](https://doi.org/10.4172/2165-7920.1000983)