

Portal Vein Thrombosis: The Overlooked Association between Pancreatic Cancer and PVT

Yasra Badi¹, Nabil Badro¹, and Shreena Dhawan^{2*}

¹Department of General and Vascular Surgeon, American University of Integrative Sciences, USA

²Medical Student of surgery, American University of Integrative Sciences, USA

Abstract

Portal vein thrombosis (PVT) is a complication of prothrombic disorders liver cirrhosis and malignancies. Pancreatic malignancy, specifically, is notorious for this complication because it upregulates tissue factor production, which activates the extrinsic coagulation cascade, thus inducing a hypercoagulable state. In this state, the body is susceptible to thrombus formation, resulting in venous thromboembolism (VTE) or PVT. Thus, considering a pancreatic malignancy as a top differential for PVT must be emphasized.

Keywords: Portal vein thrombosis; Hypercoagulable; Thromboembolism

Introduction

The portal vein forms from the convergence of the superior mesenteric and splenic veins, which drain the small intestine and spleen respectively. The portal vein can be partially or fully occluded by a blood clot, which is known as portal vein thrombosis (PVT). The clinical presentation of PVT is dependent on the duration (acute vs. chronic), extent of the thrombosis and whether collaterals have formed. This condition is caused by multiple factors, most commonly cirrhosis, and hypercoagulable states [1]. If a specific risk factor is not identified in an unexplained PVT, malignancy should be considered as a differential because of the high prevalence of PVT associated with hepatic and pancreatic malignancies. This case report will discuss the relationship between pancreatic malignancy and portal vein thrombosis as it pertains to hypercoagulability.

Case Presentation

A 69-year-old Caucasian woman presented to the emergency room due to sudden onset of right upper quadrant pain radiating to her back that began three days prior. She endorsed nausea and vomiting but denied fever, chills and hematochezia. The patient's vital signs upon arrival were: BP 116/70, Pulse 70, temperature 36.8°C, respiratory rate 18, height 175.3 cm, and weight 97.5 kg. Physical examination was significant for diffuse epigastric tenderness but no abdominal masses were appreciated on palpation. Her laboratory data demonstrated a WBC count of 7.5, lipase of 23, an elevated alkaline phosphatase at 157, a decreased CPK MB at 1.3 and an elevated PTT of 102; all other results were within normal range. Upon imaging-CAT scan, MRI and ultrasound-the patient was concluded to have portal vein thrombosis (Figure 1B), gallstones (Figure 1A), diverticulosis and some evidence of pancreatitis.

The patient's past medical history includes depression, three miscarriages, hypercholesterolemia and hypertension. She denies any history of connective tissue disorders, including lupus and rheumatoid arthritis. Past surgical history includes a hysterectomy, sling pubovaginal and colporrhaphy. Her family history was significant for stomach and colon cancer in her father. Patient is a former smoker with a 20-pack-year smoking history and reports drinking 2.4 oz of alcohol per week. The patient was started on Heparin to treat the portal vein thrombosis.

The Hematology/Oncology consult reported a normal sized liver without lesions, but with an abnormal signal within the portal veins.

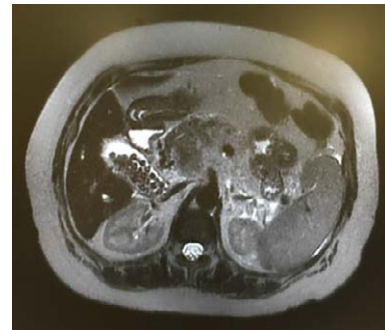


Figure 1A: Abdominal CT with contrast depicting the gallstones.

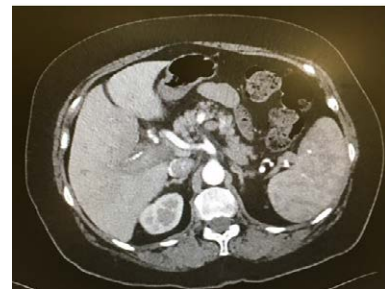


Figure 1B: Abdominal CT with contrast demonstrating portal vein thrombosis.

Edema and peripancreatic inflammatory changes were also seen. A duodenal diverticulum was visualized in the region of the pancreatic head. The patient was discharged on warfarin and with outpatient follow-up.

***Corresponding author:** Shreena Dhawan, Medical Student of Surgery, American University of Integrative Sciences, Cole Bay, USA, Tel: +16782694707; E-mail: sdhawan@auis.edu

Received: January 27, 2017; **Accepted:** March 21, 2017; **Published:** March 26, 2017

Citation: Badi Y, Badro N, Dhawan S (2017) Portal Vein Thrombosis: The Overlooked Association between Pancreatic Cancer and PVT. *Oncol Cancer Case Rep* 3: 128. doi: [10.4172/2471-8556.1000128](https://doi.org/10.4172/2471-8556.1000128)

Copyright: © 2017 Badi Y, et al. This is an open-access article distributed under the terms of the Creative Commons Attribution License, which permits unrestricted use, distribution, and reproduction in any medium, provided the original author and source are credited.

The patient returned to the emergency department with abdominal pain. A CT of the abdomen and pelvis was performed and it revealed a pancreatic mass with an area of small hypoenhancing tissue, 2.6 × 1.4 cm on slice, at the dorsal aspect of the pancreatic head (Figure 2), which was concerning for a pancreatic neoplasm, along with an adjacent portacaval lymph node, 1.4 cm in short axis. Liver metastasis, the largest mass measuring 1.2 cm, with diffuse thrombosis within intra and extrahepatic portal veins and extending into the SMV and splenic vein with cavernous transformation, was also noted. Calcified granulomata in the spleen were observed as well. Lab results demonstrated an elevated CA19-9 at 59186 U/mL (normal <34 U/mL). Endoscopic ultrasound-guided fine needle aspiration of the pancreatic head was performed and the cytology demonstrated an adenocarcinoma consistent with pancreaticobiliary primary. Immunostain for CK7 is positive with focal staining for CK20, while synaptophysin and chromogranin were negative. Thus, the entire clinical picture is suggestive of superficial thrombophlebitis/Trousseau syndrome likely secondary to her underlying metastatic pancreatic carcinoma. Markedly elevated CA19-9, portal vein thrombosis and pancreatic head fullness were all contributory factors indicative of the final diagnosis of pancreaticobiliary carcinoma.

The patient is being treated with folfirinox chemotherapy, which is often utilized for advanced pancreatic cancer.

Discussion

Portal vein thrombosis is commonly attributed to prothrombotic disorders or liver cirrhosis. However, the underlying cause of PVT in over 21% of patients was discovered to be pancreatic or hepatic malignancy [2]. Moreover, migratory thrombophlebitis has been associated with occult visceral malignancies for years [3]. Nevertheless, the association between PVT and pancreatic malignancy is overlooked in the primary list of differential diagnoses. During this patient's first visit, portal vein thrombosis had been diagnosed by a CT angiogram and determined as a possible cause of the epigastric pain. The underlying cause of this finding was unknown, but the primary differentials were a spontaneous thrombosis, a familial hypercoagulability state and liver cirrhosis. A D-dimer assay was ordered to assess the hypercoagulability, which did not result in any significant findings. Consequently, the diagnosis was delayed because pancreatic malignancy had not been one of the top choices while analyzing the patient.

PVT is a previously established complication of pancreatic cancer [4]. In a study performed by Digestive Diseases and Cancer Institutes, the frequency of PVT and venous thromboembolism in patients with pancreatic cancer was investigated. It was observed that PVT occurred

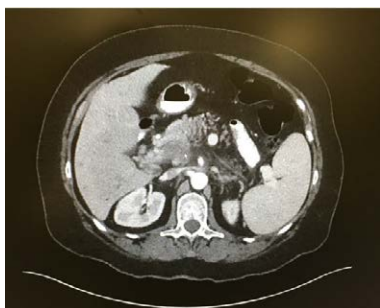

Figure 2: Abdominal CT revealing a mass on the dorsal aspect of the pancreatic head.

in 30% (32/108) patients with pancreatic cancer including 36% (17/47) of metastatic patients [4]. The patient has primary pancreaticobiliary adenocarcinoma with liver metastases and thus had a 36% likelihood of developing PVT. However, her laboratory reports did not involve researching an underlying malignancy resulting in PVT until all other differential diagnoses had been ruled out.

Although research regarding the pathophysiology behind portal vein thrombosis as a complication of pancreatic adenocarcinoma is sparse in current literature, pancreatic cancer is known to induce prothrombotic and hypercoagulable states. A study conducted by Lund University in Sweden, stated that there is a link between pancreatic cancer activating tissue factor (VII a), a primary initiator of the clotting cascade thought to be responsible for the thrombus, resulting in venous thromboembolism or PVT [5].

Tissue factor is expressed during the early stages of pancreatic malignancy and is associated with increased microvessel density and the expression of vascular endothelial growth factor (VEGF) leading to angiogenesis and, thus, tumor growth [5].

The patient's management for the portal vein thrombosis involved the implementation of low molecular weight heparin, which was eventually switched to warfarin. PVT is usually managed in this fashion unless the patient is scheduled for invasive procedures [6]. Her treatment for pancreatic cancer is a combination therapy of Folic acid, 5-Fluorouracil and Oxaliplatin) and Folfiri (Folic Acid, 5-Fluorouracil and Irinotecan) known as Folfirinnox. This is a relatively new treatment regimen for metastatic pancreatic cancer, which has suitable toxicity instances, high response rates and increased overall survival [7]. The patient endured several tests for months in order for her diagnosis to emerge even though the portal vein thrombosis had been diagnosed at her first ER visit. This indicates how crucial it is for pancreatic cancer to be among the primary differential diagnoses when a patient presents with PVT.

Conclusion

Portal vein thrombosis can be indicative of pancreatic cancer if the patient is otherwise asymptomatic. Thus, if malignancy is given the same consideration as other differential diagnoses when assessing PVT, final diagnosis of pancreatic cancer can result in more efficacious management of patients.

References

1. Sanyal AJM (2016) Acute portal vein thrombosis in adults: Clinical manifestations, diagnosis and management.
2. Ponziani FR, Zocco MA, Campanale C, Rinninella E, Tortora A, et al. (2010) Portal vein thrombosis: Insight into physiopathology, diagnosis, and treatment. *World J Gastroenterol* 16: 143-155.
3. Varki A (2007) Trousseau's syndrome: Multiple definitions and multiple mechanisms. *Blood* 110: 1723-1729.
4. Price L, Nguyen M, Picozzi V, Kozarek A (2010) Portal vein thrombosis in pancreatic cancer: Natural history, risk factors and implications for patient management, in *Gastrointestinal Cancers Symposium*, Chicago.
5. Ansari D, Andersson R, Andrén-Sandberg A (2015) Pancreatic cancer and thromboembolic disease, 150 years after Trousseau. *Hepatobiliary Surg Nutr* 4: 325-335.
6. Agnes YYL, Peterson EA (2013) Treatment of cancer-associated thrombosis. *Blood* 122: 2310-2317.
7. Rombouts SJ, Mungroop TH, Heilmann MN, van Laarhoven HW, Busch OR, et al. (2016) FOLFIRINOX in locally advanced and metastatic pancreatic cancer: A single centre cohort study. *J Cancer* 7: 1861-1866.