

Post-Finasteride Syndrome: About 2 Cases and Review of the Literature

Alejandro Silva Garreton^{1*}, Gaston Rey Valzacchi¹, Omar Layus², Leon Matusevich¹ and Guillermo Gueglio¹

¹Department of Urology, Sección Andrología, Hospital Italiano de Buenos Aires, Ciudad de Buenos Aires, Argentina

²Department of Psychiatrist, Sección Andrología, Hospital Italiano de Buenos Aires, Ciudad de Buenos Aires, Argentina

*Corresponding author: Alejandro Silva Garreton, Department of Urology, Hospital Italiano de Buenos Aires, Ciudad de Buenos Aires, Argentina, Tel: +5491163507207; E-mail: alesilvagarreton@hotmail.com

Received Date: November 02, 2016; Accepted date: December 06, 2016; Published date: December 06, 2016

Copyright: © 2016 Garreton AS, et al. This is an open-access article distributed under the terms of the Creative Commons Attribution License, which permits unrestricted use, distribution, and reproduction in any medium, provided the original author and source are credited.

Abstract

Introduction: Finasteride is widely used in the treatment of benign prostatic hyperplasia and androgenetic alopecia. Persistent sexual adverse events in patients that withdraw the drug was poorly studied. Materials and methods: case report study of two clinical cases of post-finasteride syndrome.

Case 1: 27 year old male who, after 7 months of finasteride 1mg/day intake for androgenetic alopecia, began with erectile dysfunction, low libido, hypospermia, muscular hipotrophy and penile shrinking, in a persistent and progressive way although withdrawal of the drug. He was also evaluated by a psychiatrist.

Case 2: 23 year old male that after the intake of 1 pill of finasteride 1mg for androgenetic alopecia began with erectile dysfunction, low libido, hypospermia, less intense orgasms, asthenia, muscle pain and penile shrinking, in a persistent and progressive way although withdrawal of the drug. He is under psychiatric evaluation.

Results: Case 1: Hormonal profiles were normal, with a dihydrotestosterone of 192 pg/ml and the penile ultrasound showed an hyperechogenicity at the distal portion of the right corpus cavernosum. The genetic determination of the CAG triplets of the androgen receptor gene showed a value of 24 repetitions. Treatment with Tadalafil and vacuum therapy was effective, although not complete, but he didn't benefit from the 3 month application of Andractim®, with a posterior benefit from the application of HCG 6000 UI/week associated with Anastrozole 2mg/week, with normal hormonal controls.

Case 2: penile Doppler and hormonal profiles were normal. Treatment with Tadalafil was effective, although not complete. There was no adherence to other treatments.

Conclusion: post-finasteride syndrome is a little known entity with an unknown physiopathology, and is currently under study. Awareness should be promoted about the existence of this syndrome in order to give the best assistance to these patients until we have a better comprehension of this entity.

Keywords: Finasteride; Persistent sexual adverse events; 5-alpha-reductase; 5-alpha reductase Inhibitors; Androgen receptor

Introduction

The inhibitors of the 5-alpha-reductase (5ARI), enzyme that catalyzes the conversion of Testosterone to Dihydrotestosterone (DHT) [1], have been widely used for more than 20 years, especially in the treatment of androgenetic alopecia and benign prostatic hyperplasia. There are 2 types of 5-alpha-reductase (5AR): type 1 (5AR-1) and type 2 (5AR-2). 5AR-1 is predominantly localized in hair follicles and sebaceous glands, non-genital skin, as well as in the liver, prostate and kidneys, contributing to one third of the circulating DHT. 5AR-2 is predominantly localized in the prostate, seminal vesicles, epididymis, hair follicles, genital skin and liver, contributing to the remaining two thirds of the circulating DHT [3,4]. While dutasteride is a dual inhibitor of the 5AR, finasteride only inhibits 5AR-2. 5AR is not only responsible for the reduction of Testosterone to DHT, but also for enabling the enzymatic functions of the central nervous system, in the synthesis of different neurosteroids [5]. It is clearly established that androgens are necessary not only for the development of fetal male

genitalia, but also for the maintenance of the penile structure and the erectile function, as well as an adequate spermatogenesis, in adults [6-8]. Therefore, 5ARI sexual and genital adverse effects are possible, with a reported prevalence of 10-19% in patients treated for benign prostatic hyperplasia under finasteride 5mg/day and, in patients with androgenetic alopecia under 1 mg/day, with a relative risk of 1.399[10]. Many studies have been published about this subject, with a significant variation in the presence of sexual and genital adverse effects [11-14]. Although the severity of these symptoms and the posterior withdrawal of the drug was poorly documented, Lowe, in a controlled and randomized study, which in the first year was double-blinded, reported a discontinuation of the drug due to the adverse effects of 0.2% in the placebo group, 0.7% for the finasteride 1 mg group and 1.3% in the Finasteride 5 mg group[15]. However, potential recovery after withdrawal was not assessed. In this sense, in studies conducted by Irwig et al. [16,17], the possibility that they could be permanent was established, raising awareness to the medical community respecting the use of these drugs and the study of this phenomenon, now known as Post-Finasteride Syndrome or Post 5ARI Adverse Effects Persistence Syndrome. Even though there is no consensus on the definition, most

studies believe it's required that the symptoms should last at least for 3 months [18,19]. The aim of this study is to report two cases of post finasteride syndrome, as well as a bibliographic review on the matter.

Subjects and Methods

Retrospective case report studies of 2 cases of post-finasteride syndrome. We obtained the clinical histories of the 2 patients that reported persistent adverse effects after the intake and withdrawal of Finasteride 1 mg/day that was initially indicated for androgenetic alopecia. We also showcase the complementary exams, the treatment proposed and the obtained results. Finally, we discuss a bibliographic review on the topic.

Case 1

27 year old male without any clinical or surgical antecedent of relevance. Between January and July of 2014 he was under treatment with finasteride 1mg/day for androgenetic alopecia, without any adverse effects. After a non-protected sexual relationship and the necessity to initiate prophylactic antiretroviral treatment, he suspended the intake of finasteride because of digestive intolerance, and resuming its use in September of 2014. After twenty days, he began showing signs of low libido and less morning erections, as well as penile shrinking, therefore decided to discontinue the drug 10 days later. This diminished his symptoms and he began noticing an increased libido after 2 weeks. Soon after withdrawing the drug he started to experiment the same adverse symptoms as before, associating a "flaccid but rigid" penile state, less penile length and girth, scrotal shrinking, more visible superficial penile veins, mild flaccid penile pain, mild distal penile curvature to the right, severe post ejaculatory asthenia and less muscle tone and strength. Surprisingly, he also reported not having any perceived hair loss, as if he were still under finasteride effects.

Case 2

A 23 year old male with a history of rib Ewing Sarcoma and of testicular cancer (unilaterally orchiectomized), both pathologies for which he underwent chemo and radiotherapy treatment, free of disease for the past 5 years, and without any endocrine, osteomuscular, psychosexual, erectile or ejaculatory function disorder. Due to his androgenetic alopecia, treatment with Finasteride 1 mg/day was indicated. The day after having his first pill, he noticed adverse effects attributable to this drug, so he decided to discontinue the drug.

These symptoms consisted of severe erectile dysfunction (which ranged from progressive worsening to complete erectile dysfunction), lack of any morning erections, less penile length and girth which caused "excessive penile skin", penile hyposensitivity, more visible superficial penile veins, moderate penile, testicular and perineal pain (with progressive and spontaneous improvement), hypospermia and a "more watery" semen, less intense orgasms, asthenia and articular and muscular pain (but without any muscle mass loss), that also showcased progressive and spontaneous improvement.

Other nonspecific symptoms were: intense headaches that progressively improved ocular and retroocular pain, miodesopsias, xerofthalmia, red eyes and photophobia, with progressive improvements except for the miodesopsias, insomnia, panic attacks and mood disorders.

Results

Case 1

Upon physical examination, a little fibrous plaque was found at the distal portion of the right corpus cavernosum, that the patient denied noticing before, with no further findings. A hormonal profile was performed in two opportunities (LH, FSH, Total and bioavailable Testosterone, Estradiol, Prolactine, TSH, SHBG and DHEA-S), as well as a penile ultrasound and a derivation to Psychiatry for interdisciplinary work after he began showing suicidal tendencies. It was not possible to determine serum DHT because it's not measured in Argentina on adult patients. However, both hormonal profiles, without DHT, were normal. Due to his previously known anxious personality and the psychopathology triggered after these events, following his psychiatric evaluation, treatment with benzodiazepines was indicated, resulting in some improvement in the penile size.

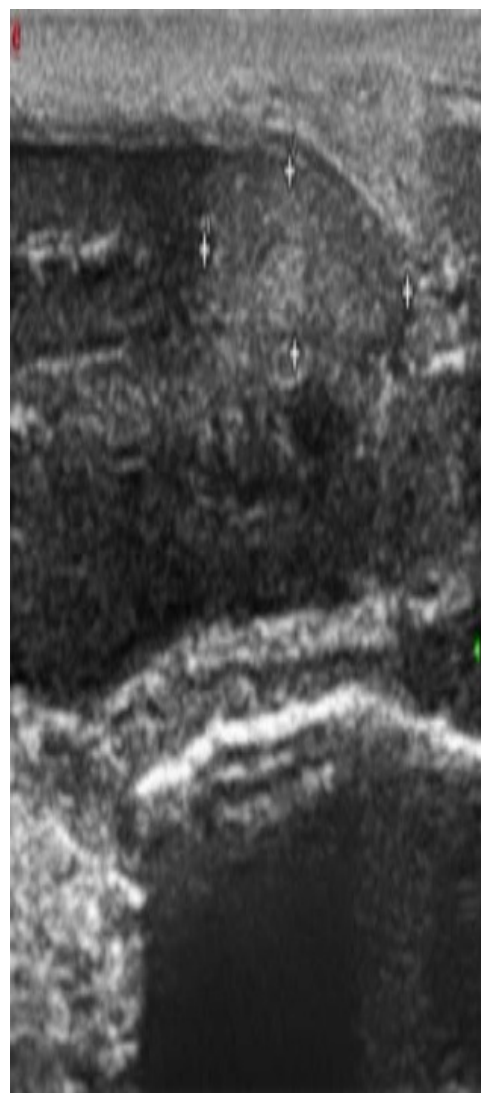


Figure 1: Intracavernosal hyperechogenicity of distal portion of right corpus cavernosum.

The penile ultrasound showed a plaque at the distal portion of the right corpus cavernosum associated to an intracavernosal hyper echogenicity (Figure1), as if it could be an intracavernosal fibrosis. Consequently, a penile Magnetic Resonance Imaging (MRI) under vasoactive drugs was performed, with normal results and without any suggestive finding (Figure 2).

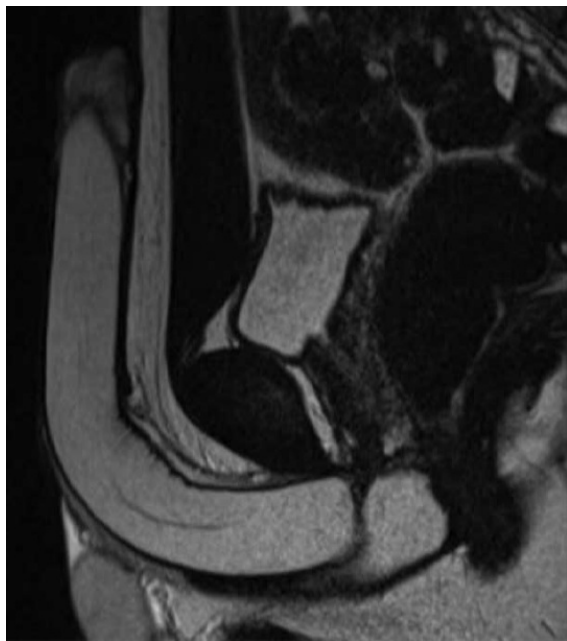

Figure 2: Normal penile MRI (under vasoactive drugs).

The main treatment consisted in Tadalafil 5 mg/day and vacuum therapy, with a favorable but partial response. Being that the diagnostic hypothesis consisted in a drop in the serum levels of DHT, we indicated DHT replacement treatment with Andractim® (2.5% DHT gel) 5 gm per day. Since no clinical response was seen after 3 months of use, it was discontinued. It's important to clarify that while the dosage was decided according to the treatment of hypogonadism, there is no guideline on the replacement of DHT in patients with this syndrome. After all he had been through, the patient went for a medical consultation at Baylor College of Medicine, Houston, Texas, USA. He wanted to have his DHT levels measured and opt for an alternative treatment. A DHT measurement was performed, as well as a genetic analysis of CAG triplet repeats of the androgen receptor gene, since polymorphisms at this level could be associated to its lower sensitivity to androgens. DHT resulted in a value of 192 pg/ml (112-955 pg/ml), interpreted as a low DHT for his age. CAG determination resulted in 24 repetitions, interpreted as significant for lower sensitivity of the androgen receptor. After this evaluation, the indicated treatment consisted of HCGu 6000 UI/week, divided into 3 applications of 2000 UI/week, combined with Anastrozole 2 mg/week, divided into 2 intakes of 1 mg/week. This was done in order to hyper stimulate the Leydig cells, elevate the levels of Testosterone and blocking the aromatase, thus diverting the metabolism of Testosterone through the 5AR way (assuming it still had any remaining activity), without compromising his spermatogenesis (Figure 3).

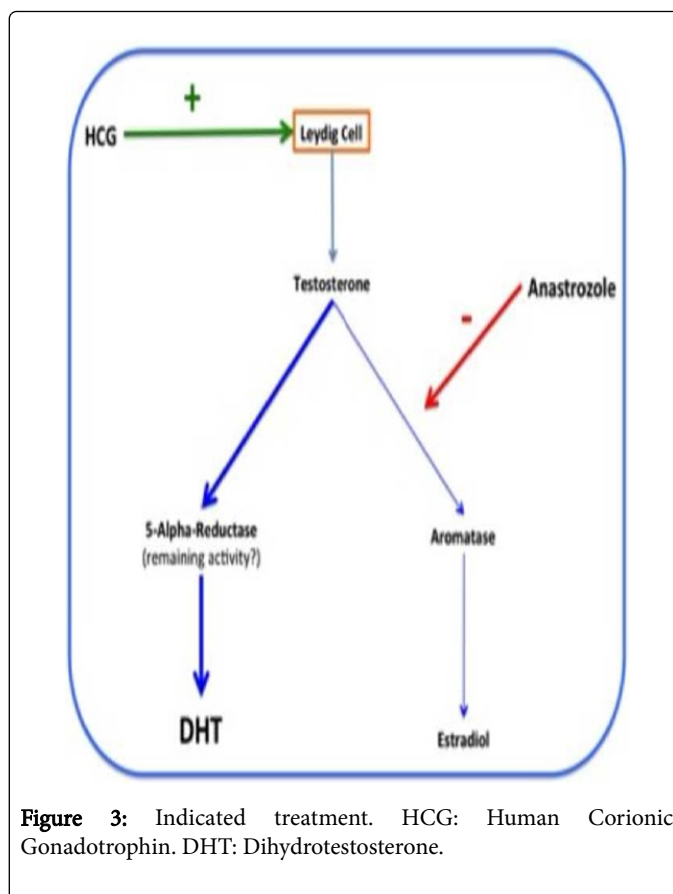


Figure 3: Indicated treatment. HCG: Human Corionic Gonadotrophin. DHT: Dihydrotestosterone.

After 2 weeks of treatment he noticed some improvements, such as less penile rigidity in a flaccid state, a more “warm” penis, increased morning erections (without any changes in the rigidity of the erections), some growth in penile girth, absence of post ejaculatory asthenia, greater libido, increase in muscular tone and strength, and an improved mood and self-esteem. One month later, a hormonal profile was performed without DHT, showing a Testosterone of 10.2 ng/ml (2.5-8.5 ng/ml), a bioavailable Testosterone of 6.14 ng/ml, and an Estradiol in range, so we decided to lower the dose of HCGu to 5000 UI/week. Two months after this treatment modification, a new hormonal profile was taken, which showed a Testosterone of 7.93 ng/ml, a bioavailable Testosterone of 2.42 ng/ml and an Estradiol in range. This resulted in a more comfortable treatment (given that HCGu is marketed in 5000 UI flasks) as well as a higher sense of well-being. He is currently still under treatment, with a slow but steady improvement in his symptoms, accompanied by periodic evaluation by the Andrology team of the Urology department and the Psichiarty department of the Hospital Italiano from Buenos Aires.

Case 2

A hormonal profile (LH, FSH, Total and bioavailable Testosterone, Estradiol, Prolactine, TSH, SHBG and DHEA-S) and a penile ecodoppler with vasoactive drugs were indicated. The hormonal profile came back normal, and was further confirmed by a second one two months later. The only altered item found was FSH, which resulted in values of 16 and 21 mU/ml, surely due to the unilateral orchidectomy and the chemo and radiotherapy treatment, with a severe negative impact in his spermatogenesis. It was not possible to determine serum

DHT levels because they're not measured in Argentina on adult patients. The penile ecdoppler results were normal. He mentioned that the erectile function improved after the indication of Tadalafil 5 mg/day. Even though masturbation was difficult, he was able to penetrate, ejaculate and orgasm during sexual intercourse. Unfortunately, an increased sexual anxiety prevented him from performing normally. He also noticed a mild improvement in penile size. A few weeks after being on Tadalafil, he suspended it due to headaches and tinnitus, only to resume it intermittently when the symptoms disappeared. He had no adherence to any other treatment alternatives. He was interdisciplinary evaluated along with a psychiatrist, to attend his psychosexual, mood and anxiety disorders. He is currently being treated with benzodiazepines (with adequate response), and is still under periodic evaluation by the Andrology team of the Urology department and the Psychiatry department of the Hospital Italiano from Buenos Aires.

Discussion

The impact of finasteride on a patient's sexuality is well known, though poorly studied, especially in regard to the physiopathology of the maintenance and progression of the symptoms after the drug has been withdrawn. The prevalence or incidence of this syndrome is unknown, although some authors have tried to estimate it, as is the case of the study published by Wessells et al. [20], randomized, double-blinded, with a 4 year follow-up of a total of 30-40 patients, which estimated the incidence of adverse effects of the treatment with finasteride 5 mg/day for benign prostatic hyperplasia versus placebo. 15% of the patients in the case group reported sexual adverse effects, against a 7% in the placebo group. These adverse effects resolved without withdrawing the drug in 12% and 19%, respectively. 4% of the patients under finasteride suspended it, and 50% of them didn't resolve the symptoms; 2% of the patients in the placebo group suspended it, and up to a 59% of them didn't resolve the symptoms. Nevertheless, there are no prospective and randomized studies against placebo that can approximate us to a real prevalence, especially in patients with androgenetic alopecia that suspended finasteride after experiencing its sexual adverse effects. On the other hand, Mondaini et al. proposed the possibility of a placebo effect after they were warned of the possible sexual adverse effects of taking finasteride, showing that 30.9% made reference to erectile dysfunction, while 9.6% of those who weren't warned about this mentioned erectile dysfunction [21]. Both of the patients in our case series experienced a decreased libido, erectile dysfunction and less morning erections, as well as penoscrotal morphological changes, particularly penile and scrotal shrinking, and hypospermia, that lasted for more than 3 months. All of these symptoms are consistent with different studies that evaluated them in these patients [22-26]. Many experimental publications in animals have left clear the importance of DHT in the erectile function [27-29]. Park et al. showed that androgens, without differences between Testosterone and DHT, are crucial for the proper maintenance of the expression of nitric oxide synthetase, which explains the differences in response to phosphodiesterase inhibitors between normo and hypogonadic patients [30]. The patient in case 1 presented a severe anxiety syndrome, associated with suicidal ideation, that required for an interdisciplinary management with a psychiatrist. Many studies suggest that different neurosteroids, like allopregnenolone (among others) could be involved in different neuronal circuits, such as anxiety and depression regulation [31-35]. 5AR is fundamental for the biosynthesis of these neurosteroids, followed by a second enzymatic step mediated by a 3-alpha reductase. In fact, finasteride reduces not

only the plasma levels, but also the cephalorraquid fluid levels of these neurosteroids [35]. Because not all of the patients that withdrew finasteride after experiencing its sexual adverse effects persisted with these symptoms, there could be some type of genetic predisposition. This is why several authors have put their focus on disorders of the 5AR and of the androgen receptor. Di Loreto et al. showed their experience in patients with persistent symptoms after withdrawing finasteride 1mg/day for androgenetic alopecia who had undergone a foreskin biopsy in order to determine androgen receptor density, resulting much higher in cases than in controls. This data could imply a fundamental role of 5AR in the expression of the androgen receptor18. However, evidence differs in some in vitro studies with prostate cancer cells exposed to finasteride, in which the expression of the androgen receptor is downregulated [36], although the physiopathology could differ with a different population or target. On the other hand, different polymorphisms of the exon 1 of the androgen receptor gene are implicated in its affinity to androgens. Cecchin et al. showed an association between the expansion mutation of CAG and GGN triplets, androgenetic alopecia and the possibility of developing a post-finasteride syndrome, resulting in a higher number of triplet repetitions in those patients with androgenetic alopecia and, especially, in those who developed the syndrome (Table 1)[37].

p*	PM CAGn (repetitions)			p*	PN GGNn (repetitions)			p*
	19-26	<19 ° >26	OR (CI 95%)		23-24	<23 ° >24	OR (CI 95%)	
No-AA	94.7 %	5.3%	-	-	96.1 %	3.9%	-	-
AA	83.5 %	16.5 %	3.55(1,1 3-11,21)	0.028	84.4 %	15.6 %	4.6 (1,27-16, 69)	0.019
AA +PFS	75.4 %	24.6 %	5.88(1,8 7-18,52)	0.002	79.7 %	20.3 %	6.36(1,7 4-23,23)	0.003

Table 1. Comparative distribution of CAG and GGN alleles in the different groups of patients.

The polymorphism of this exon of the gene is directly related to its overexpression and inversely related to the sensitivity of the androgen receptor [38,39]. However, in an up to date of Shukla et al. [40] about androgen receptor related diseases, it's well established the inverse relationship between the number of CAG repetitions and the sensitivity of the androgen receptor, but isn't that clear for GGN repetitions. In fact, controversially, a study by Gao et al. showed a lower sensitivity of this receptor when there's a deletion of this gene region [41]. The number of repetitions is a fundamental factor not only because it determines the sensitivity of the androgen receptor, but also for its association (usually above 40 repetitions) with the bulbospinal muscular atrophy or Kennedy disease, a neurodegenerative disease due to toxicity secondary to overexpression of the androgen receptor in the motoneurons [42]. These patients can experience, besides the neurologic symptoms, microrchidia, gynecomastia and oligo or azoospermia, among other sexual and reproductive symptoms. This is why it is hypothesized that post-finasteride syndrome patients could carry an expansion mutation of the CAG and/or GGN triplet of exon 1 of the androgen receptor gene, although lower than 40 repetitions, resulting in a silent mutation, becoming evident after the inhibition of the 5AR. When the levels of DHT drop drastically, Testosterone becomes the main androgen, with a lower affinity to an already

defective receptor. Because this doesn't explain the persistence of the symptoms after the discontinuation of the drug, other cofactors may be involved. This is why the focus is also onto the expression and activity of the 5AR. Bechis et al. reported the development of resistance to the treatment of benign prostatic hyperplasia with finasteride 5 mg/day in a subgroup of patients, that after a prostatic biopsy showed a lower density of epithelial and stromal 5AR by immunohistochemistry, probably due to epigenetic changes of the gene [19]. Berman et al. had already reported that, in the urogenital tract of the adult rat, Testosterone and DHT positively regulate 5AR-2, data corroborated by Torres et al. in the adult brain of the rat [43,44]. Therefore, DHT seems to be a positive regulator of the expression of the 5AR, and its downregulation due to lack of DHT could explain the persistence of the symptoms. Also, proapoptotic effects of finasteride may be involved, as showed by Traish et al. not only in the corpora cavernosa but also in the central nervous system [45]. These results seem counterintuitive in respect to the classic feedback mechanisms, and opens a field of investigation into the regulation of the expression of the 5AR that could clarify the physiology of androgen action and the physiopathology of this syndrome. It's logical to interpret that the neuropsychiatric symptoms that are constantly reported by these patients could be due to a negative impact of the physical symptoms in their mood. However, as previously mentioned, many neurosteroids such as allopregnenolone, whose metabolism depends of the 5AR (among other enzymes), have a fundamental role in mood regulation, among other neurologic functions [46]. In fact, Melcangi et al. demonstrated a lower concentration of these neurosteroids in the cephalorraquid fluid compared to controls [35]. Also, it's not clear if the diminished levels of these neurosteroids in the cephalorraquid fluid were present before the installation of the syndrome, given that patients without post-finasteride syndrome (but with depressive symptoms) also have low cephalorraquid levels of neurosteroids, especially allopregnenolone [5]. The presence of mood disorders, and even suicidal ideation that is observed in these patients is a fundamental aspect to have in mind for their interdisciplinary management. Suicidal ideation is especially important when the persistence and progression of the symptoms lasts more than 3 months [47]. Recently, Basaria et al. didn't find evidence of sequence variation in AR, SRD5A1, or SRD5A2 genes, or of significant alterations in expression of AR-dependent genes in the skin, but they can't exclude the possibility of variations in other genes, like epigenetic effects, or in the gene expression levels in other tissues or specific brain regions involved in regulation of mood and sexual function. Therefore, symptomatic finasteride users are unlikely to benefit from treatment with testosterone, DHT, or any other androgen because these patients didn't show evidence of androgen deficiency, persistent SRD5A inhibition or androgen insensitivity [48]. In our experience, both patients reported adverse effects attributable to the use of finasteride, being both cases very similar between them, except for the fact that one of them only needed one pill of finasteride 1 mg to experience its adverse effects and, after the withdrawal of the drug, its persistence and progression, warning about a possible time and/or dose independent characteristic of the syndrome. Another fundamental difference between both patients is that one of them reported to have developed a penile curvature, later evidencing a plaque on the right corpus cavernosum and an ultrasound showing an apparent intracavernosal fibrosis, that we couldn't corroborate with an MRI. Although the patient did mention that the curvature developed after the use of finasteride, we can't be sure about this. However, some studies associate the state of hypogonadism as a risk factor for the

development of Peyronie's disease, so the drop in the levels of DHT could have been a factor in the development of his curvature [49,50].

Conclusions

Persistent adverse effects after finasteride withdrawal include a wide variety of symptoms that range from erectile dysfunction to low libido, ejaculatory, osteomuscular and even neuropsychiatric disorders. This syndrome still lacks of a precise definition, although some diagnostic guidelines are showing up. The symptoms reported in this and other related publications, as well as clinical suspicion, are fundamental in the evaluation and diagnosis of these patients, but especially important in their emotional support, given that they don't usually find an answer to their problems. Since it's not currently possible to predict which patients are at risk of suffering this syndrome, more studies are required in order to prevent its occurrence, and explain its physiopathology and optimum treatment. The majority of these studies refer to patients under finasteride for androgenetic alopecia. It would be interesting to develop more studies in patients under finasteride for benign prostatic hyperplasia, as well as those treated with dutasteride. This is the first study developed in Argentina about post-finasteride syndrome, and we believe that it's an important contribution to raise awareness about its existence in order to improve the treatment of these patients until we can better understand this entity.

References

1. Russell DW, Wilson JD (1994) Steroid 5 alpha-reductase: two genes/two enzymes. *Annu Rev Biochem* 63: 25-61.
2. Thiboutot D, Harris G, Iles V, Cimic G, Gilliland, K et al. (1995) Activity of the type 1 5-alpha-reductase exhibits regional differences in isolated sebaceous glands and whole skin. *J Invest Dermatol* 105: 209-214.
3. Thigpen AE, Silver RI, Guileyardo JM, Casey ML, McConnell JD, et al. (1993) Tissue distribution and ontogeny of steroid 5 alpha-reductase isozyme expression. *J Clin Invest* 92: 903-910.
4. Gislakog PO, Hermann D, Hammarlund-Udenaes M, Karlsson MO (1998) A model for the turnover of dihydrotestosterone in the presence of the irreversible 5-alpha-reductase inhibitors GI198745 and finasteride. *Clin Pharmacol Ther* 64: 636-647.
5. Schüle C, Nothdurfter C, Rupprecht R (2014) The role of allopregnenolone in depression and anxiety. *Progress in Neurobiology* 113: 79-87.
6. Gooren LJ, Saad F (2006) Recent insights into androgen action on the anatomical and physiological substrate of penile erection. *Asian J Androl* 8: 3-9.
7. Traish AM, Guay AT (2006) Are androgens critical for penile erections in humans? Examining the clinical and preclinical evidence. *J Sex Med* 3: 382-404.
8. Shen ZJ, Lu YL, Chen ZD, Chen F, Chen Z (2000) Effects of androgen and ageing on gene expression of vasoactive intestinal polypeptide in rat corpus cavernosum. *BJU Int* 86: 133-137.
9. Marberger MJ (1998) Long-term effects of finasteride in patients with benign prostatic hyperplasia: a double-blind, placebo-controlled, multicenter study. *Urology* 51: 677-686.
10. Mella JM, Perret MC, Manzotti M, Catalano HN, Guyatt G (2010) Efficacy and safety of finasteride therapy for androgenetic alopecia. *Arch Dermatol* 146: 1141-1150.
11. Gormley GJ, Stoner E, Bruskewitz RC, Imperato-McGinley J, Walsh PC, et al. (1992) The effect of finasteride in men with benign prostatic hyperplasia. *N Engl J Med* 327: 1185-1191.
12. Stoner E. (1994) Three-year safety and efficacy data on the use of finasteride in the treatment of benign prostatic hyperplasia. *Urology* 43: 284-292.

13. Nickel JC, Fradet Y, Boake RC, Pommerville PJ, Perreault JP (1996) Efficacy and safety of finasteride therapy for benign prostatic hyperplasia: results of a 2-year randomized controlled trial. *CMAJ* 155: 1251-1259.
14. Debruyne FM, Jardin A, Colloi D, Resel L, Witjes WP (1998) Sustained-release alfuzosin, finasteride and the combination of both in the treatment of benign prostatic hyperplasia. *Eur Urol* 34: 169-175.
15. Lowe FC, McConnell JD, Hudson PB, Romas NA, Boake R, et al. (2003) Long-term 6-year experience with finasteride in patients with benign prostatic hyperplasia. *Urology* 61: 791-796.
16. Irwig M, Kolukula S (2011) Persistent sexual side effects of finasteride for male pattern hair loss. *J Sex Med* 8: 1747-1753.
17. Irwig M (2012) Persistent sexual side effects of finasteride: could they be permanent? *J Sex Med* 9: 2927-2932.
18. Di Loreto C, La Marra F, Mazzon G, Belgrano E, Trombetta C et al. (2014) Immunohistochemical evaluation of androgen receptor and nerve structure density in human prepuce from patients with persistent sexual side effects after finasteride use for androgenetic alopecia. *PLoS One*: 9.
19. Bechis SK, Otsetov AG, Ge R, Olumi AF (2014) Personalized medicine for the management of benign prostatic hyperplasia. *J Urol* 192: 16-23.
20. Wessells H, Roy J, Bannow J, Grayhack J, Matsumoto AM, et al. (2003) Incidence and severity of sexual adverse experiences in finasteride and placebo-treated men with benign prostatic hiperplasia. *Urology* 61: 579-584.
21. Mondaini N, Gontero P, Giubilei G, Lombardi G, Cai T, et al. (2007) Finasteride 5 mg and sexual side effects: how many of these are related to a nocebo phenomenon? *J Sex Med* 4: 1708-1712.
22. Chiriaco G, Cauci S, Mazzon G, Trombetta C (2016) An observational retrospective evaluation of 79 young men with long-term adverse effects after use of finasteride against androgenetic alopecia. *Andrology* 4: 245-250.
23. Canguven O, Burnett AL (2008) The effect of 5- α -reductase inhibitors on erectile function. *J Androl* 29: 514-523.
24. Canguven O, Talib RA (2013) Persistent sexual side effects of finasteride: Could they be permanent? *J Sex Med* 10: 1441.
25. Mysore V (2012) Finasteride and sexual side effects. *Indian Dermatol Online J* 3: 62-65.
26. Ganzer CA, Jacobs AR, Iqbal F (2015) Persistent sexual, emotional, and cognitive impairment post-finasteride: a survey of men reporting symptoms. *Am J Mens Health* 9: 222-228.
27. Bradshaw WG, Baum MJ, Awh CC (1981) Attenuation by a 5 alpha-reductase inhibitor of the activational effect of testosterone propionate on penile erections in castrated male rats. *Endocrinology* 109: 1047-1051.
28. Lugg JA, Rajfer J, Gonzalez-Cadavid NF (1995) Dihydrotestosterone is the active androgen in the maintenance of nitric oxide-mediated penile erection in the rat. *Endocrinology* 136: 1495-1501.
29. Baum MJ, Canick JA, Erskine MS, Gallagher CA, Shim JH (1983) Normal differentiation of masculine sexual behavior in male ferrets despite neonatal inhibition of brain aromatase or 5-alpha-reductase activity. *Neuroendocrinology* 36: 277-284.
30. Park KH, Kim SW, Kim KD, Paick JS (1999) Effects of androgens on the expression of nitric oxide synthase mRNAs in rat corpus cavernosum. *BJU Int* 83: 327-333.
31. Rupprecht R (1997) The neuropsychopharmacological potential of neuroactive steroids. *J Psychiatr Res* 31: 297-314.
32. Rupprecht R, Holsboer F (1999) Neuropsychopharmacological properties of neuroactive steroids. *Steroids* 64: 83-91.
33. Traish AM, Hassani J, Guay AT, Zitzmann M, Hansen ML (2011) Adverse side effects of 5- α reductase inhibitors therapy: Persistent diminished libido and erectile dysfunction and depression in a subset of patients. *J Sex Med* 8: 872-884.
34. Ayad KA, Balraj SH, Mahyar E (2015) Persistent sexual dysfunction and suicidal ideation in young men treated with low-dose finasteride: a pharmacovigilance study. *Pharmacotherapy* 35: 687-695.
35. Melcangi RC, Caruso D, Abbiati F, Giatti S, Calabrese D, et al. (2013) Neuroactive steroid levels are modified in cerebrospinal fluid and plasma of post-finasteride patients showing persistent sexual side effects and anxious/depressive symptomatology. *J Sex Med* 10: 2598-2603.
36. Wang LG, Mencher SK, McCarron JP, Ferrari AC (2004) The biological basis for the use of an anti-androgen and a 5- α -reductase inhibitor in the treatment of recurrent prostate cancer: case report and review. *Oncol Rep* 11: 1325-1329.
37. Cecchin E, De Mattia E, Mazzon G, Cauci S, Trombetta C, et al. (2014) A pharmacogenetic survey of androgen receptor (CAG)_n and (GGN)_n polymorphisms in patients experiencing long term side effects after finasteride discontinuation. *Int J Biol Markers* 29: 310-316.
38. Chamberlain N, Driver E, Miesfeld R (1994) The Length and Location of Cag Trinucleotide Repeats in the Androgen Receptor N-Terminal Domain Affect Transactivation Function. *Nucleic Acids Res* 22: 3181-3186.
39. Tut T, Ghadessy F, Trifiro M, Pinsky L, Yong E (1997) Long polyglutamine tracts in the androgen receptor are associated with reduced trans-activation, impaired sperm production, and male infertility. *J Clin Endocrinol Metab* 82: 3777-3782.
40. Shukla GC, Plaga AR, Shankar E, Gupta S (2016) Androgen receptor-related diseases: what do we know? *Andrology*. 4: 366-381.
41. Gao T, Marcelli M, McPhaul MJ (1996) Transcriptional activation and transient expression of the human androgen receptor. *J Steroid Biochem Mol Biol* 59: 9-20.
42. Valera Yepes R, Virgili Casas M, Povedano Panades M, Guerrero Gual M, Villabona Artero C (2015) Enfermedad de Kennedy y resistencia parcial androgénica. Descripción de 4 casos y revisión de la literatura. *Rev Endocrinol Nutr* 62: 224-230.
43. Berman DM, Tian H, Russell DW (1995) Expression and regulation of steroid 5-alpha-reductase in the urogenital tract of the fetal rat. *Mol Endocrinol* 9: 1561-1570.
44. Torres JM, Ortega E (2003) Differential regulation of steroid 5-alpha-reductase isozymes expression by androgens in the adult rat brain. *Faseb J* 17: 1428-1433.
45. Traish AM, Mulgaonkar A, Giordano N (2014) The dark side of 5 alpha-reductase inhibitors' therapy: sexual dysfunction, high gleason grade prostate cancer and depression. *Korean J Urol* 55: 367-379.
46. Dubrovsky B (2006) Neurosteroids, neuroactive steroids, and symptoms of affective disorders. *Pharmacol Biochem Behav* 84: 644-655.
47. Irwig M (2012) Depressive symptoms and suicidal thoughts among former users of finasteride with persistent sexual side effects. *J Clin Psychiatry* 73: 1220-1223.
48. Basaria S, Jasuja R, Huang G, Wharton W, Pan H, et al. (2016) Characteristics of men who report persistent sexual symptoms after finasteride use for hair loss. *J Clin Endocrinol Metab* 101: 4669-4680
49. Zhou-Jun S, Xie-Lai Z, Ying-Li L, Zhao-Dian C (2003) Effect of androgen deprivation on penile ultrastructure. *Asian J Androl* 5: 33-36.
50. Moreno SA, Morgentaler A (2009) Testosterone deficiency and Peyronie's disease: pilot data suggesting a significant relationship. *J Sex Med* 6: 1729-1735.