

Ruptured Mycotic Aortic Aneurysm Secondary to *Escherichia Coli* Bacteremia in an HIV-Positive Patient

Nicholas David Ward and Jean Marie Ruddy*

Department of Surgery, Medical University of South Carolina, USA

Abstract

Mycotic aortic aneurysms are an aggressive form of degenerative remodeling reported more commonly in immunosuppressed patients. These aneurysms carry a high risk of progression to rupture, fulminant sepsis, and death, and therefore require prompt operative intervention. The human immunodeficiency virus (HIV) has also been associated with a broad spectrum of vascular disease, including development of aneurysms, however these have typically been identified in the peripheral vasculature. We report the case of a 71-year-old, HIV-positive male who presented with *Escherichia coli* bacteremia and aortitis which rapidly progressed to a ruptured infrarenal mycotic aortic aneurysm. He was managed successfully with open debridement and *in situ* implantation of a rifampin-soaked prosthetic graft as well as long-term antibiotic therapy. Here, we review the epidemiology, pathophysiology, and optimal surgical treatment of mycotic aortic aneurysms.

Keywords: Aortic aneurysms; Epidemiology; *Escherichia coli*

Introduction

HIV-related vasculopathy comprises a broad spectrum of disease, including occlusive disease, aneurysm formation, and microangiopathy [1,2]. HIV-related aneurysmal disease has been shown to be a distinct pathologic entity from atherosclerotic and mycotic aneurysms [3] and can be distinguished by several features—the presence of multiple aneurysms in atypical locations, younger patient age, fewer traditional atherosclerotic risk factors, and unique histopathology defined by peri-adventitial inflammatory infiltrates [4-8]. It remains unclear to what extent direct viral action versus opportunistic bacterial infection is responsible [2]. Mycotic aortic aneurysms (MAA) are also a rare and highly morbid subset of abdominal aortic aneurysms (AAA), comprising only 0.7% to 1.8% of all AAA [4,5]. Management of MAA has been a challenging problem for the vascular surgeon, as it often presents late in the course of disease in immunocompromised hosts and carries a high risk of progression to rupture, fulminant sepsis, and death [4,5]. MAA traditionally mandates operative intervention in the form of *in situ* graft placement or extra-anatomic bypass followed by aortic debridement and ligation, though successful endovascular management has recently been described for non-ruptured MAA [6,7]. Commonly implicated organisms include *Staphylococcus* and *Salmonella* species, with *Escherichia coli* less frequently identified [4,8]. In the HIV-infected population, MAA secondary to opportunistic pathogens have also been reported [9,10], and this report focuses on an unusual case of rapidly progressive, ruptured MAA in an HIV-positive patient successfully managed with *in situ* prosthetic reconstruction.

Case Report

A 71 year-old male with past medical history significant for hypertension, HIV, benign prostatic hypertrophy, and tobacco abuse presented to a community hospital complaining of several weeks of escalating back pain. The patient's HIV has been well-controlled on HAART therapy with Genvoya (Elvitegravir, Cobicistat, Emticitabine, Tenofovir Alafenamide), with recent CD4 count of 524/mm³ and an undetectable viral load. On physical exam, he had mild abdominal and flank tenderness as well as palpable femoral pulses. Following surgical consultation, a CT scan of the abdomen and pelvis was performed which revealed penetrating aortic ulcers of the infrarenal aorta and significant peri-aortic stranding consistent with aortitis. Maximal aortic diameter was 2.5 cm (Figure 1a). He was managed non-operatively with broad-spectrum antibiotics, and de-escalated to ceftriaxone after *E.*

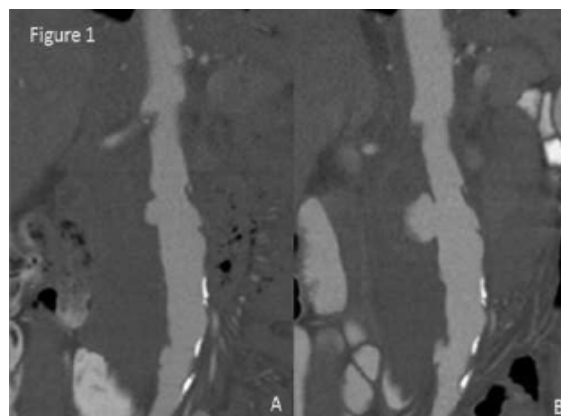


Figure 1: Coronal CT projections demonstrating (A) penetrating aortic ulcer with peri-aortic stranding consistent with infrarenal aortitis, and (B) rapid progression to mycotic aortic aneurysm with contained rupture.

coli was isolated from blood cultures on the second day of admission. Repeat blood cultures after 48 hours of antibiotic therapy were negative, suggesting clearance of the patient's bacteremia. On hospital day nine, however, the patient developed acute worsening of his back pain. A repeat CT aortogram of the abdomen and pelvis revealed progression of the penetrating aortic ulcer to a saccular mycotic aortic aneurysm with extraluminal contrast consistent with contained rupture (Figure 1b). The patient remained hemodynamically stable, and was subsequently transferred to the Medical University of South Carolina Aortic Center.

Upon the patient's arrival, impulse control was initiated with nicardipine and Esmolol infusions, with goal heart rate <70 beats per minute and goal systolic blood pressure <130 mmHg. His white blood

*Corresponding author: Jean Marie Ruddy, Department of Surgery, Medical University of South Carolina, USA, Tel: 8438764855; E-mail: ruddy@musc.edu

Received March 03, 2017; Accepted March 22, 2017; Published March 27, 2017

Citation: Ward ND, Ruddy JM (2017) Ruptured Mycotic Aortic Aneurysm Secondary to *Escherichia Coli* Bacteremia in an HIV-Positive Patient. J Clin Case Rep 7: 941. doi: 10.4172/2165-7920.1000941

Copyright: © 2017 Ward ND, et al. This is an open-access article distributed under the terms of the Creative Commons Attribution License, which permits unrestricted use, distribution, and reproduction in any medium, provided the original author and source are credited.

cell count was within normal limits at this time. He was taken emergently to the operating room for open repair through a midline laparotomy. The supraceliac aorta was exposed for emergency control as needed and the infrarenal aorta was approached near the bifurcation. Dense periaortic inflammation was encountered which had distorted the ureteral anatomy and was accompanied by caseating granulomatous changes in the nearby lymph nodes. The left and right common iliac segments were cleared for clamp placement and following careful mobilization of the left ureter and duodenum, the inferior mesenteric artery was controlled. Moving proximally, it was clear that the densely inflamed and adherent left renal vein could not be salvaged. Additional dissection established space for clamp placement below the bilateral renal arteries, and following systemic heparinization, the infrarenal aorta was clamped. The aortotomy was extended from the bifurcation cranially through the left renal vein and this ligation was buttressed with nearby inflammatory tissue. Patent lumbar arteries were oversewn and the aortic wall was resected as able. More specifically, the region of rupture was debrided, including evacuation of retroperitoneal thrombus, and the cavity was thoroughly irrigated with antibiotic solution. Tissue culture was sent from this region. An interposition graft was then performed using a rifampin-soaked 14 mm × 7 mm Hemashield bifurcated graft (Maquet, Rastatt, Germany). Given the healthy appearance of the tissue at the bifurcation, the limbs were trimmed, effectively creating a tube graft. The proximal and distal anastomoses were created using 3-0 prolene suture in circumferential running fashion, and an omental flap was created and fastened into place over the graft with running 2-0 vicryl suture. Given patent hypogastric arteries bilaterally and the presence of brisk back-bleeding from the inferior mesenteric artery, it was not re-implanted. The abdomen was irrigated with antibiotic solution and closed.

The patient's post-operative course was complicated by acute kidney injury secondary to contrast nephropathy, but this returned to baseline by post-operative day 4 and the remainder of his recovery was uneventful. HAART therapy was maintained throughout his hospitalization and an emphasis was placed on post-operative nutrition. Intra-operative tissue culture was positive for pan-sensitive *E. coli*, and the patient was maintained on a six-week course of IV ceftriaxone with plans for long-term oral suppression therapy per the infectious disease specialists. He was discharged to a rehabilitation facility on post-operative day ten.

Discussion

Mycotic aneurysms may affect any artery, with the aorta, peripheral arteries, cerebral vessels, and visceral arteries affected in descending order of frequency [11,12]. Mycotic aortic aneurysms (MAA) comprise only a small minority of aortic aneurysms [4,5] and have been associated with an aggressive course with rapid progression. A large contemporary series of MAA have reported a high frequency of rupture at the time of presentation, ranging from 38% to 85% [4,6,8] with in-hospital mortality as high as 36% to 40% [5,13]. Causative organisms most frequently include *Salmonella* species and *Staphylococcus aureus*, with *Streptococcus* species and *E. coli* identified less commonly. In the majority of patients, at least one comorbid condition causing immunosuppression can be identified, including diabetes mellitus, steroid use, and chronic renal failure [4]. Additionally, it has been reported that nearly half of all patients presenting with MAA had a recent infection, including pneumonia, cholecystitis, urinary tract infection, endocarditis, and diverticulitis [4,5]. MAA have also been described in the HIV-positive population in association with opportunistic pathogens, such as *Mycobacterium avium* and *Listeria monocytogenes* [9,10].

HIV-related vasculopathy comprises a broad spectrum of disease, including retinopathy, microangiopathic glomerular disease, occlusive

disease, and aneurysm formation. HIV-related aneurysms often occur in multiple and atypical locations, preferentially affecting the carotid and superficial femoral arteries [1,3,14]. Typical histologic features include leukocytoclastic vasculitis of the vasa vasora and periadventitial vessels, chronic inflammation, and medial fibrosis with loss of elastic and muscular tissue [3,15]. While the etiology of HIV-related aneurysms remains unclear, it has been hypothesized that immunosuppression in HIV-positive patients makes them more susceptible to bacteremia and secondary mycotic aneurysm formation [1,2]. In this case, it has been suspected that the patient's back and flank pain reflected underlying urinary tract infection, subsequently leading to bacteremia and seeding of the aorta with progression to MAA.

Given the high risk of morbidity and mortality, as evidenced by this patient's progression to rupture in a matter of days, prompt operative intervention with debridement of infected aortic tissue is considered critical to management of MAA. Potential operative approaches include aortic ligation with extra-anatomic bypass, *in situ* reconstruction, and endovascular repair. Traditionally, aortic ligation with extra-anatomic bypass, such as axillary-femoral bypass grafting, has been advocated in cases of infrarenal aneurysms to avoid late infective complications [5,16]. Unfortunately, extra-anatomic bypass has been associated with higher rates of peri-operative complications and decreased long-term patency. Previous studies, for example, have reported a 20% risk of aortic stump disruption, a 20% to 29% amputation rate, and a 20% risk of reinfection [4,17]. *In situ* graft reconstruction, on the other hand, has been shown in multiple studies to be a safe and durable option, with no significant difference in graft-related complications or long-term survival [4,16,18]. To further reduce the risk of infection, most authors recommend use of a rifampin-soaked graft and buttressing of repair with an omental flap, if technically feasible [5,19]. Alternatively, recent studies have demonstrated the safety, efficacy, and feasibility of endovascular management of MAA, which has been shown to offer improved short-term survival relative to open surgery without an increased incidence of infectious complications or need for reoperation [7]. However, in cases of MAA with rupture at the time of presentation, most authors continue to recommend open surgical management [6]. As the vascular surgeon's armamentarium expands, thoughtful consideration of individual patient factors will be critical to improving outcomes and providing the best care possible.

Conclusion

Aortic aneurysm formation in HIV-infected patients may be due to a viral-induced angiopathy but bacterial infection may also contribute in the immunocompromised host. Mycotic aortic aneurysms typically have an aggressive and highly morbid course; therefore a high index of suspicion is critical to ensure timely diagnosis and prompt surgical intervention.

References

1. Botes K, van Marle J (2007) Surgical intervention for HIV related vascular disease. *Eur J Vasc Endovasc Surg* 34(4): 390-396.
2. Robbs JV, Paruk N (2010) Management of HIV vasculopathy: A South African experience. *Eur J Vasc Endovasc Surg* 39(Suppl 1): S25-S31.
3. Nair R, Robbs JV, Naidoo NG, Woolgar J (2000) Clinical profile of HIV-related aneurysms. *Eur J Vasc Endovasc Surg* 20(3): 235-240.
4. Oderich GS, Panneton JM, Bower TC, Cherry KJ Jr, Rowland CM, et al. (2001) Infected aortic aneurysms: aggressive presentation, complicated early outcome, but durable results. *J Vasc Surg* 34(5): 900-908.
5. Muller BT, Wegener OR, Grabitz K, Pillny M, Thomas L, et al. (2001) Mycotic aneurysms of the thoracic and abdominal aorta and iliac arteries:

- Experience with anatomic and extra-anatomic repair in 33 cases. J Vasc Surg 33(1): 106-113.
6. Kan CD, Lee HL, Yang YJ (2007) Outcome after endovascular stent graft treatment for mycotic aortic aneurysm: a systematic review. J Vasc Surg 46(5): 906-912.
 7. Sorelius K, Wanhainen A, Furebring M, Bjorck M, Gillgren P, et al. (2016) Nationwide study of the treatment of mycotic abdominal aortic aneurysms comparing open and endovascular repair. Circulation 134(23): 1822-1832.
 8. Hsu RB, Chen RJ, Wang SS, Chu SH (2004) Infected aortic aneurysms: Clinical outcome and risk factor analysis. J Vasc Surg 40(1): 30-35.
 9. Tsilimparis N, Defreitas D, Debus ES, Reeves JG (2014) Latent mycobacterium avium infection causing a mycotic suprarenal aortic aneurysm in a human immunodeficiency virus-positive patient. Ann Vasc Surg 28(4): 1035.e1031-1034.
 10. Gunst JD, Jensen-Fangel S (2014) A mycotic abdominal aortic aneurysm caused by Listeria monocytogenes in a patient with HIV infection. BMJ case reports 2014.
 11. Lee WK, Mossop PJ, Little AF (2008) Infected (mycotic) aneurysms: Spectrum of imaging appearances and management. Radiographics: A review publication of the radiological society of North America Inc. 28(7): 1853-1868.
 12. McCready RA, Bryant MA, Divilbiss JL, Chess BA, Chitwood RW, et al. (2006) Arterial infections in the new millenium: an old problem revisited. Ann Vasc Surg 20(5): 590-595.
 13. Fillmore AJ, Valentine RJ (2006) Surgical mortality in patients with infected aortic aneurysms. J Am Coll Surg 196(3): 435-441.
 14. Padayachy V, Robbs JV (2012) Carotid artery aneurysms in patients with human immunodeficiency virus. J Vasc Surg 55(2): 331-337.
 15. Chetty R, Batitang S, Nair R (2000) Large artery vasculopathy in HIV-positive patients: Another vasculitic enigma. Hum pathol 31(3): 374-379.
 16. Lee CH, Hsieh HC, Ko PJ, Li HJ, Kao TC, et al. (2011) *In situ* versus extra-anatomic reconstruction for primary infected infrarenal abdominal aortic aneurysms. J Vasc Surg 54(1): 64-70.
 17. Moneta GL, Taylor LM, Jr., Yeager RA, Edwards JM, Nicoloff AD, et al. (1998) Surgical treatment of infected aortic aneurysm. Am j surg 175(5): 396-399.
 18. Lee CH, Hsieh HC, Ko PJ, Chou AH, Yu SY (2014) Treatment of infected abdominal aortic aneurysm caused by Salmonella. Ann Vasc Surg 28(1): 217-226.
 19. Bandyk DF, Novotney ML, Johnson BL, Back MR, Roth SR (2001) Use of rifampin-soaked gelatin-sealed polyester grafts for *in situ* treatment of primary aortic and vascular prosthetic infections. J surgi res 95(1): 44-49.

Citation: Ward ND, Ruddy JM (2017) Ruptured Mycotic Aortic Aneurysm Secondary to Escherichia Coli Bacteremia in an HIV-Positive Patient. J Clin Case Rep 7: 941. doi: [10.4172/2165-7920.1000941](https://doi.org/10.4172/2165-7920.1000941)

OMICS International: Open Access Publication Benefits & Features

Unique features:

- Increased global visibility of articles through worldwide distribution and indexing
- Showcasing recent research output in a timely and updated manner
- Special issues on the current trends of scientific research

Special features:

- 700+ Open Access Journals
- 50,000+ editorial team
- Indexing at major indexing services
- Rapid review process
- Quality and quick editorial, review and publication processing
- Indexing at major indexing services
- Sharing Option: Social Networking Enabled
- Authors, Reviewers and Editors rewarded with online Scientific Credits
- Better discount for your subsequent articles

Submit your manuscript at: <http://www.omicsonline.org/submission/>